

ENT Update 7th Feb 08

*David Strachan
ENT Consultant,
Bradford
Royal
Infirmary*





Basic Questions

1. Draw a normal eardrum
2. What normal structures can you see up a nose
3. What is a cholesteatoma
4. What is the commonest way for an acoustic neuroma to present
5. What may cause a facial palsy

TOPICS

- TAKING A HISTORY
- (EXAMINATION)
- AUDIOGRAMS & HEARING LOSS
- CHRONIC EAR DISEASE
- VERTIGO
- TINNITUS
- GLUE EAR (TARGET STUDY)
- RHINITIS / SINUSITIS
- NECK & THROAT SYMPTOMS
 - HOARSE VOICE
 - DYSPHAGIA
 - THYROID / NECK LUMP
- ANYTHING ELSE

Back to basics



Audiology course

Diagnostic Strategy

David Strachan FRCS
ENT Consultant
Bradford Royal Infirmary

The History

- The most important part of the strategy

- Take time
 - Be thorough
 - Be structured

HISTORY TAKING: SUGGESTED SEQUENCE

- Introduction
- Presenting complaint
- History of current illness
- Systemic enquiry
- Past medical history
- Drugs and allergies
- Family history
- Social and personal history
- Patient's ideas, concerns and expectations.

Diagnostic strategy ...

- History taking
 - a differential diagnosis is already in mind
- Examination
- Investigation

EXAMINATION - EAR

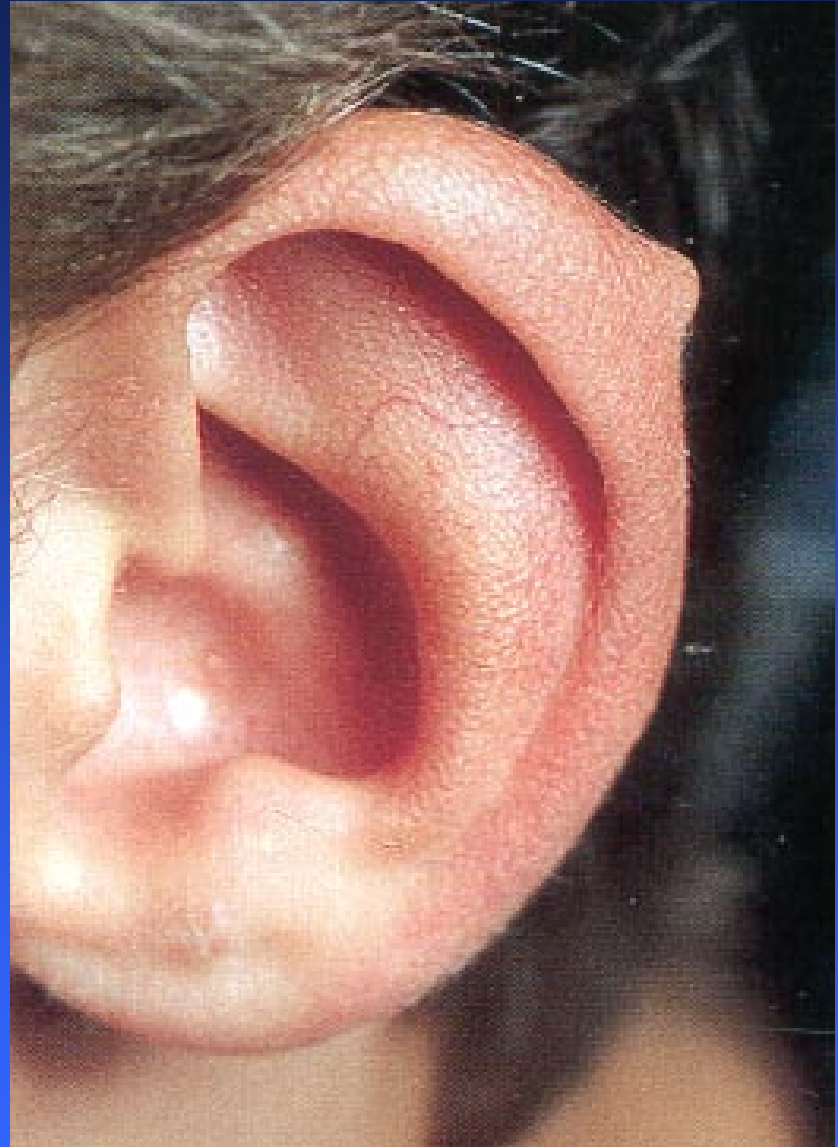


EXAMINATION - EAR

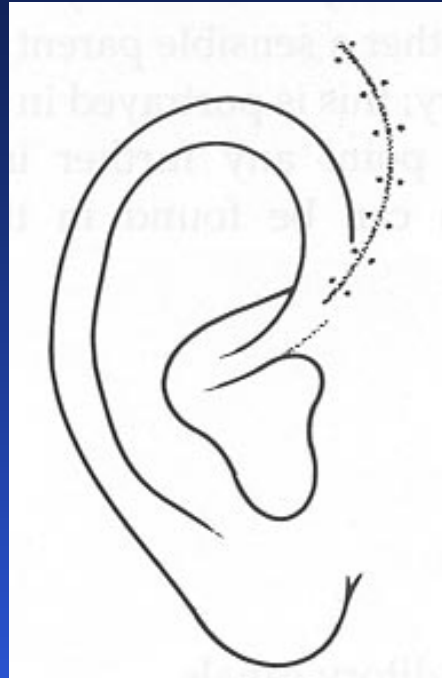- External Inspection
- Palpation
- Auriscope
- (Hearing assessment)

External Inspection

*Is there an
external
deformity?*

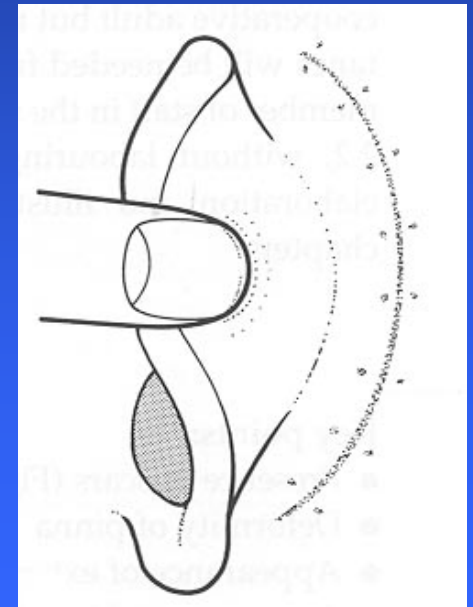


External
Inspection



Endaural

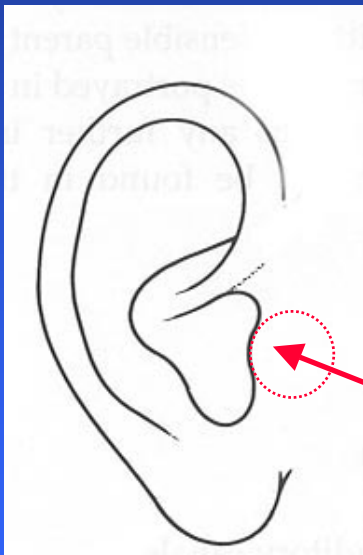
Postauricular



Are there any scars?

EXTERNAL EXAMINATION OF EAR

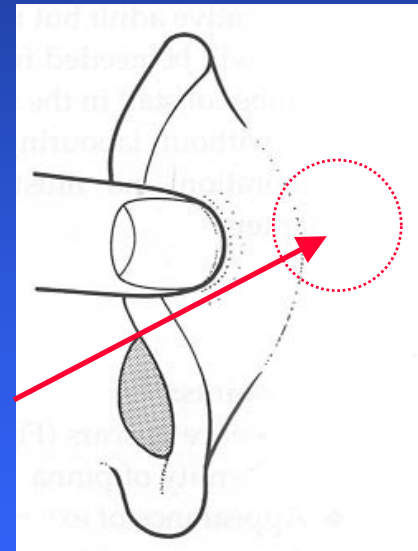
Palpation




Tragus

Is it tender?

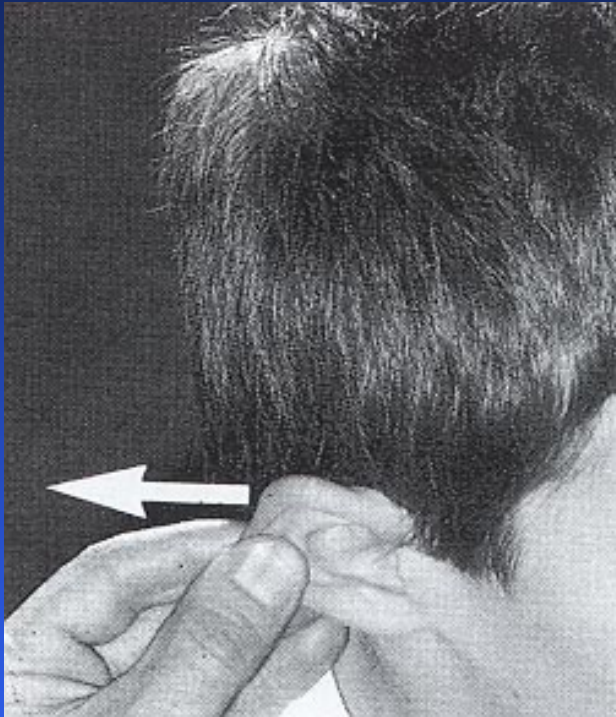
Postaural



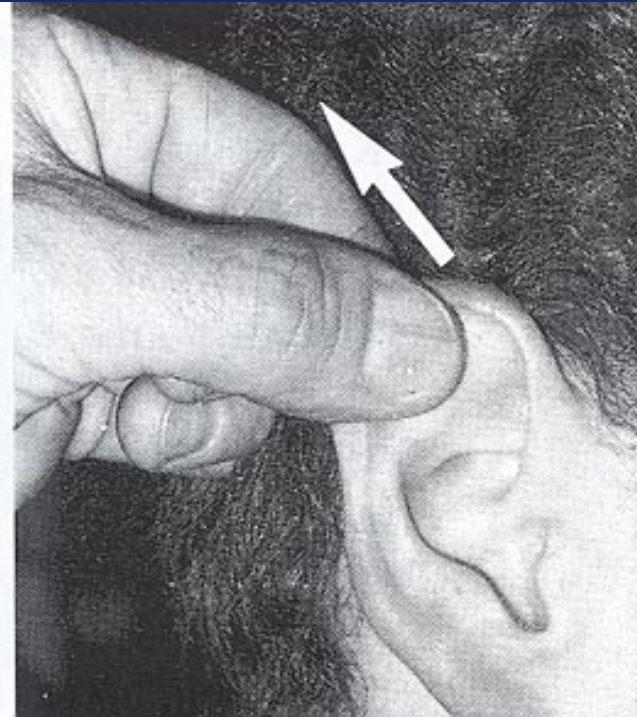
Auriscopes Examination



Auriscope Examination

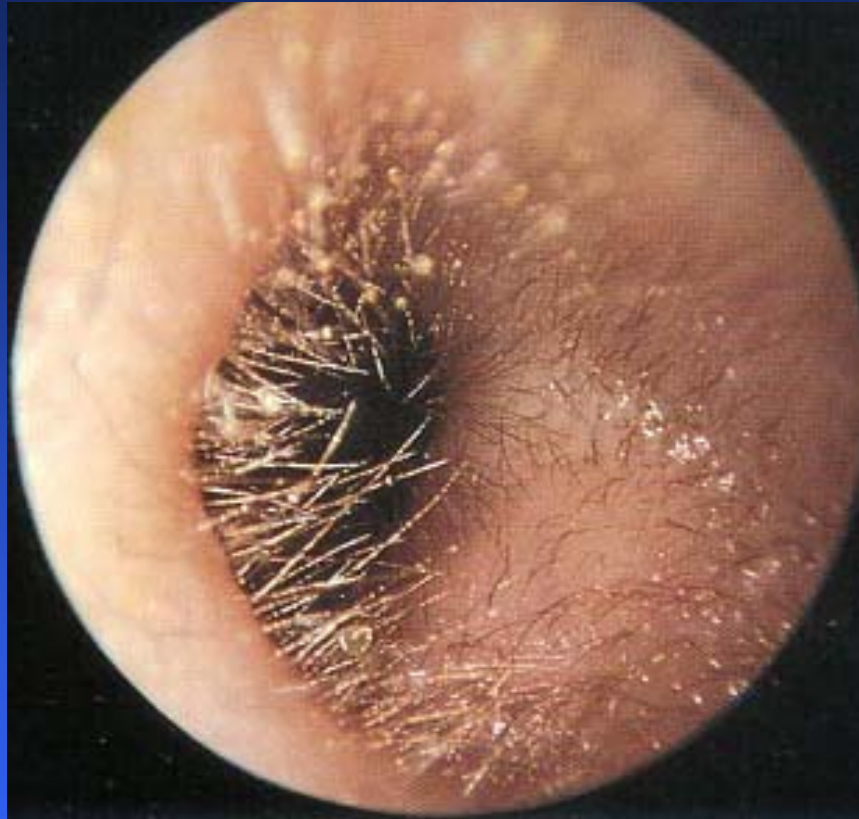


Child
Posterior



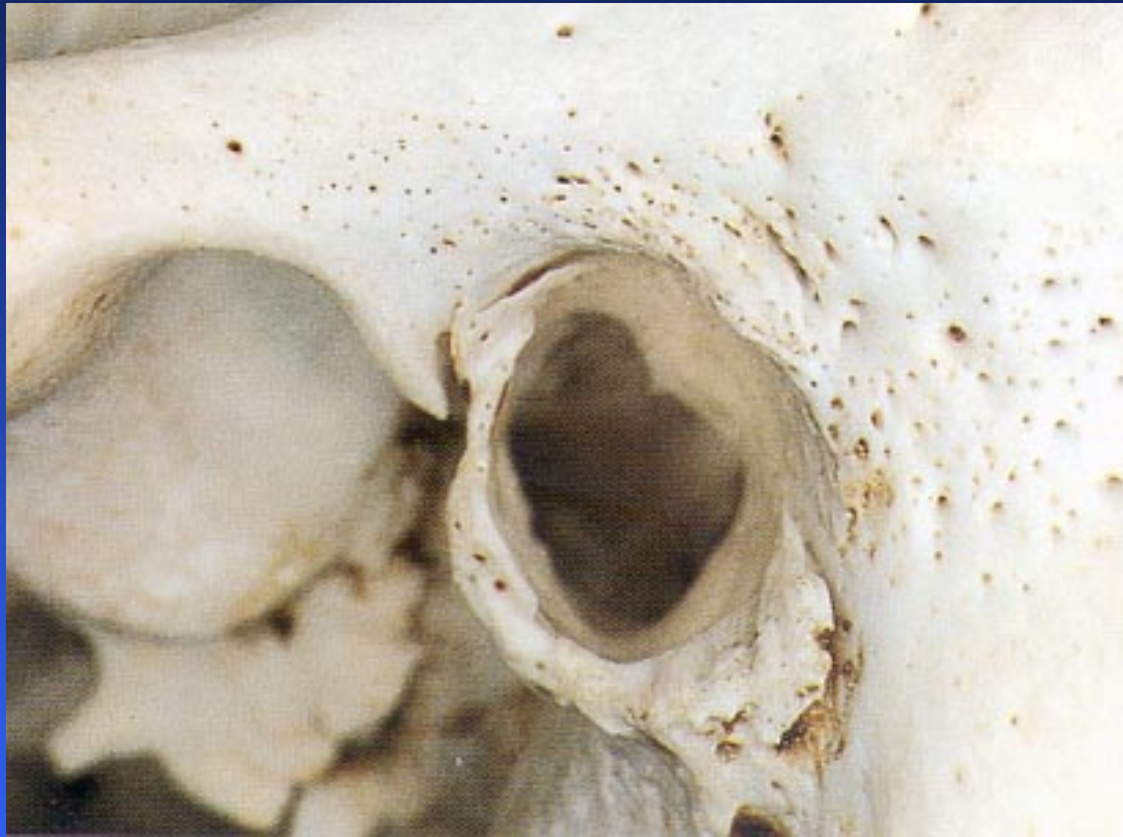Adult
Posterior-
Superior

Auriscope Examination



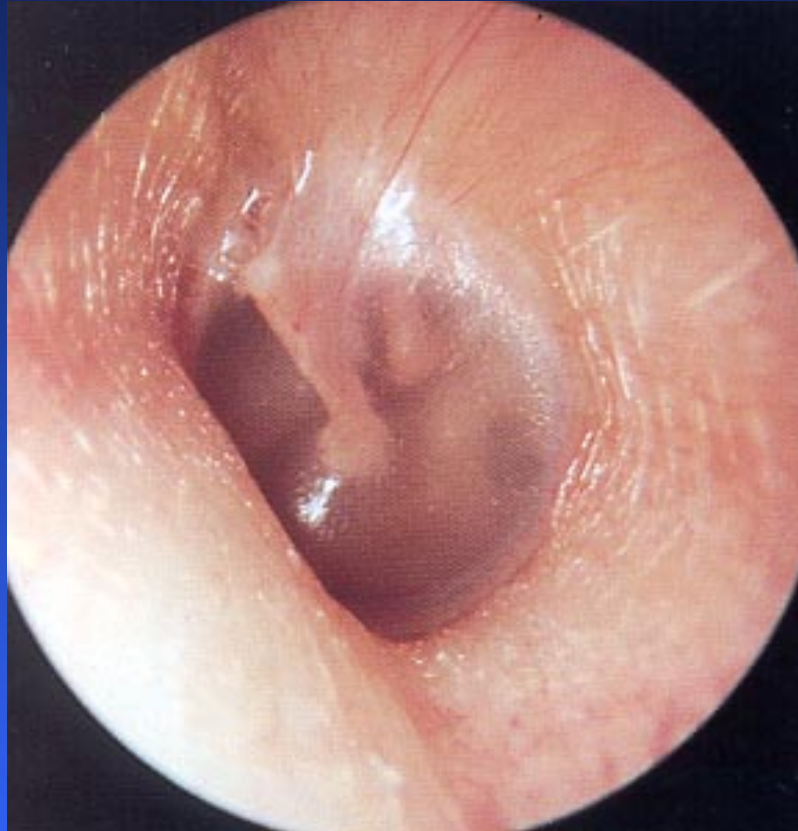Cartilagenous
External Auditory Canal

Auriscope Examination



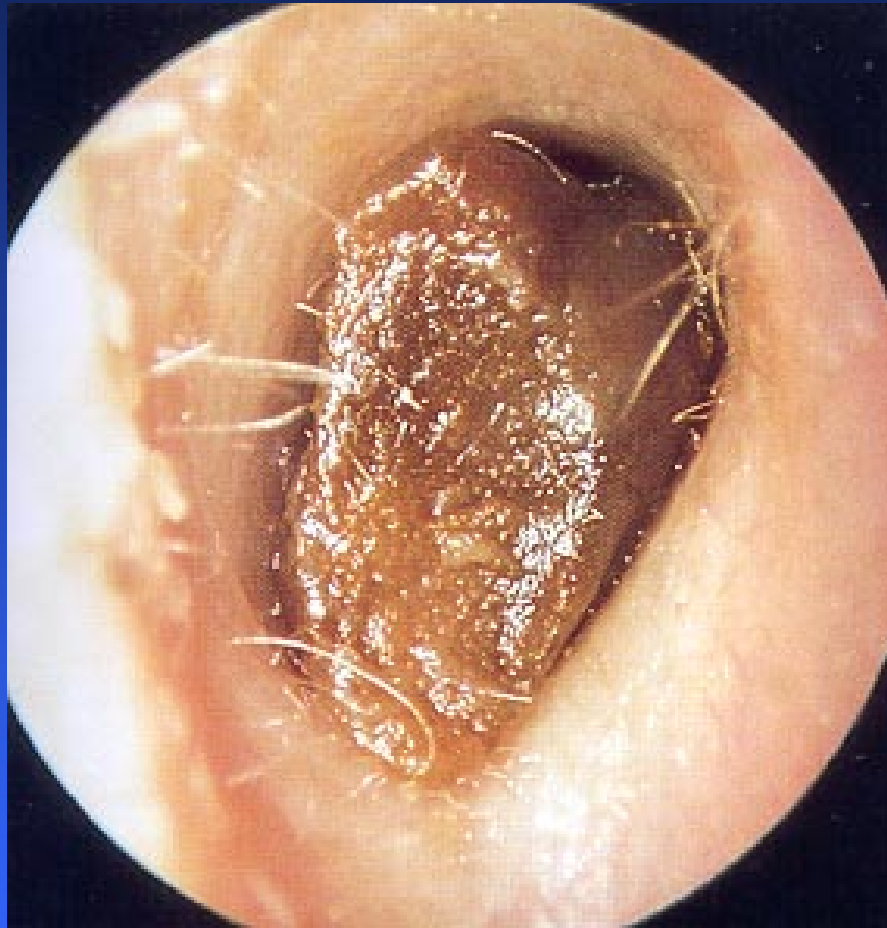Bony
External Auditory Canal

Auriscope Examination



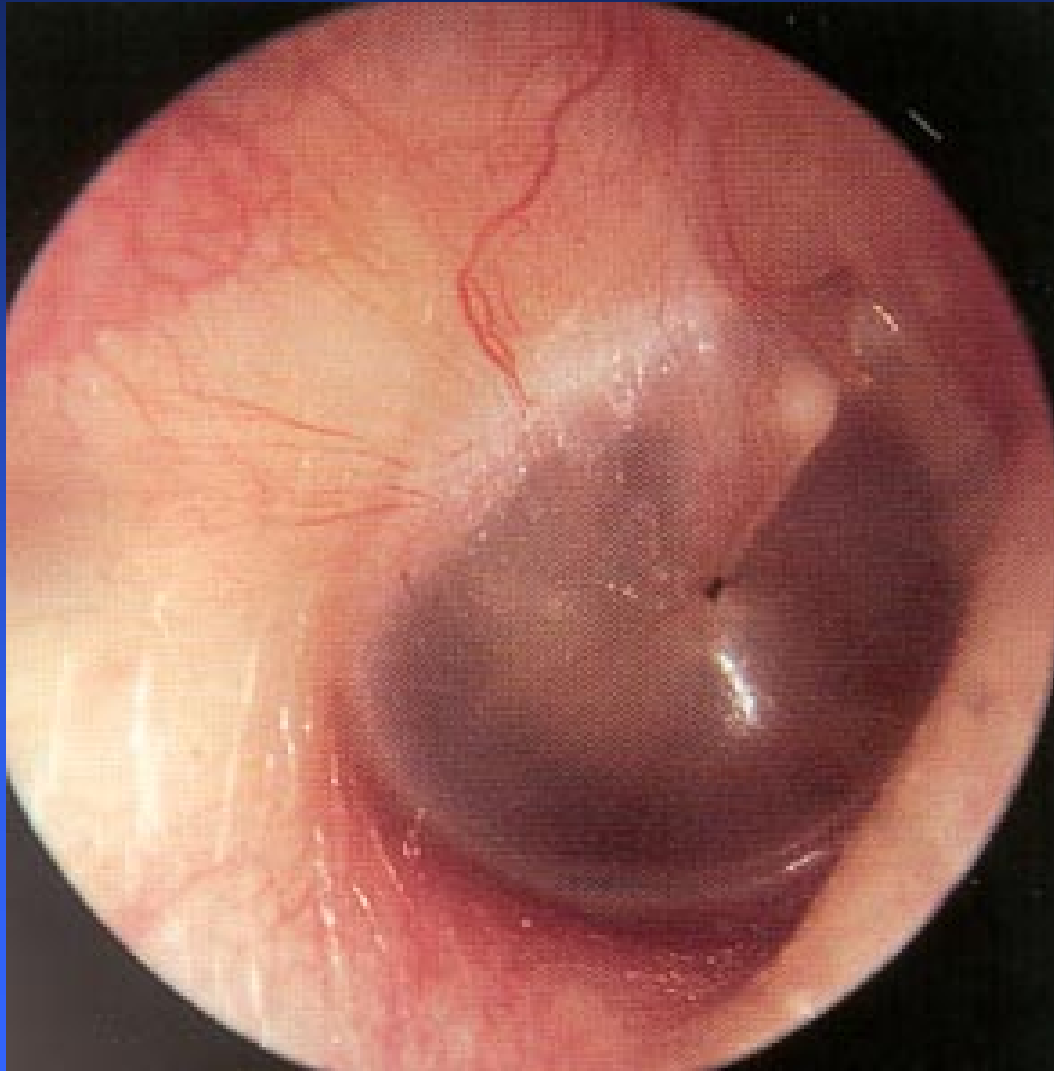Bony External Auditory Canal
& Tympanic Membrane

Auriscope Examination

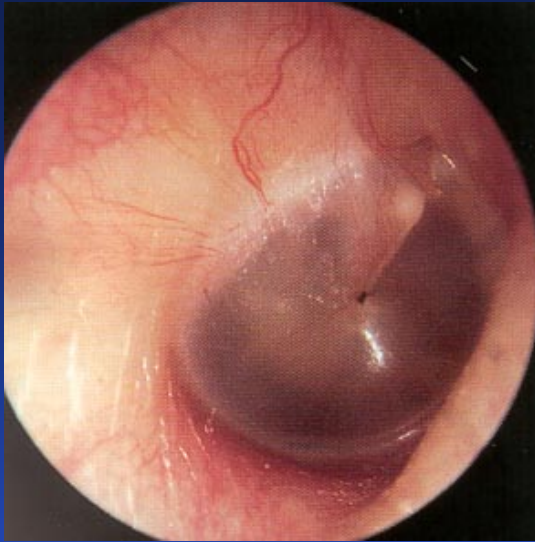


Wax

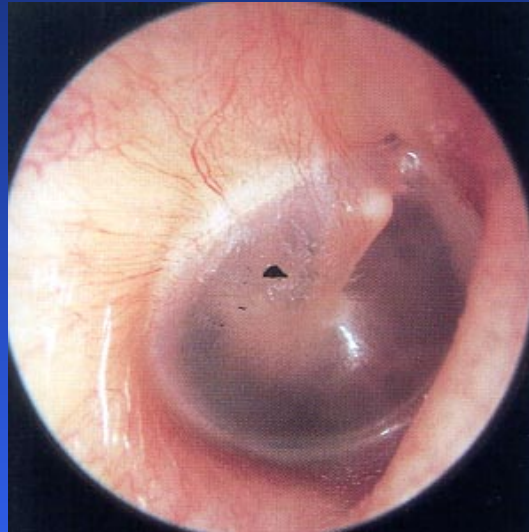
Epithelial Migration



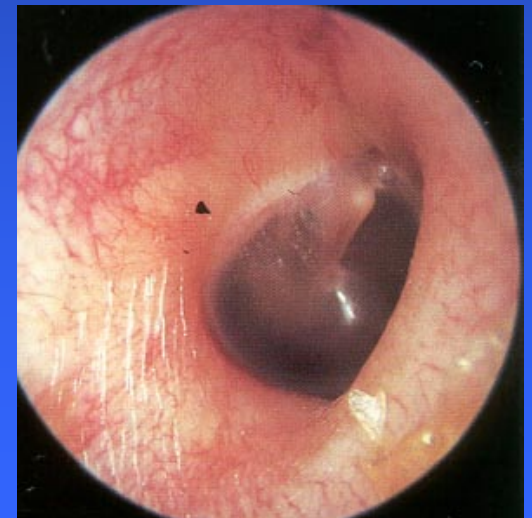
Epithelial Migration



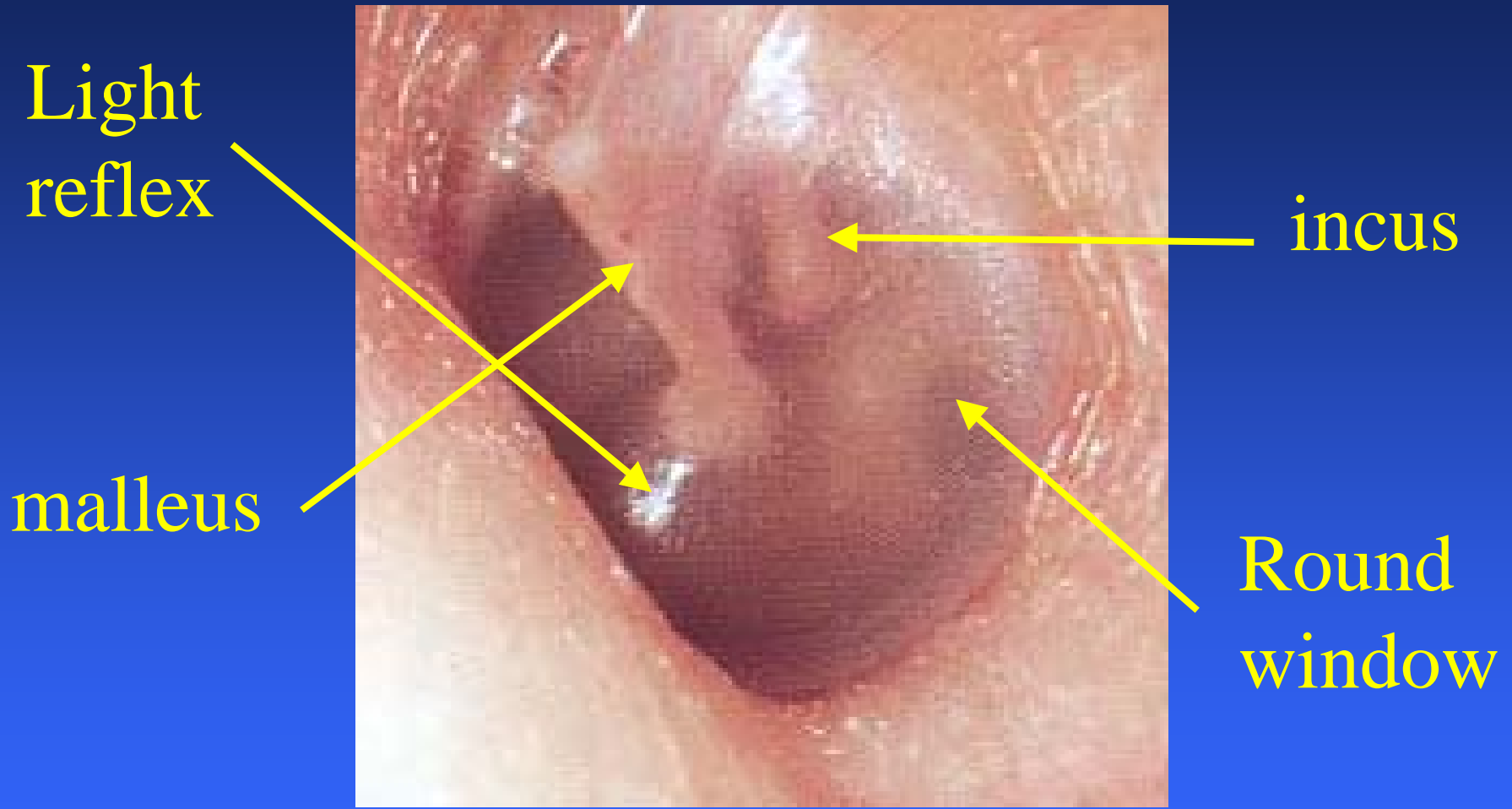
2 months



4 months



Auriscope Examination



Light reflex

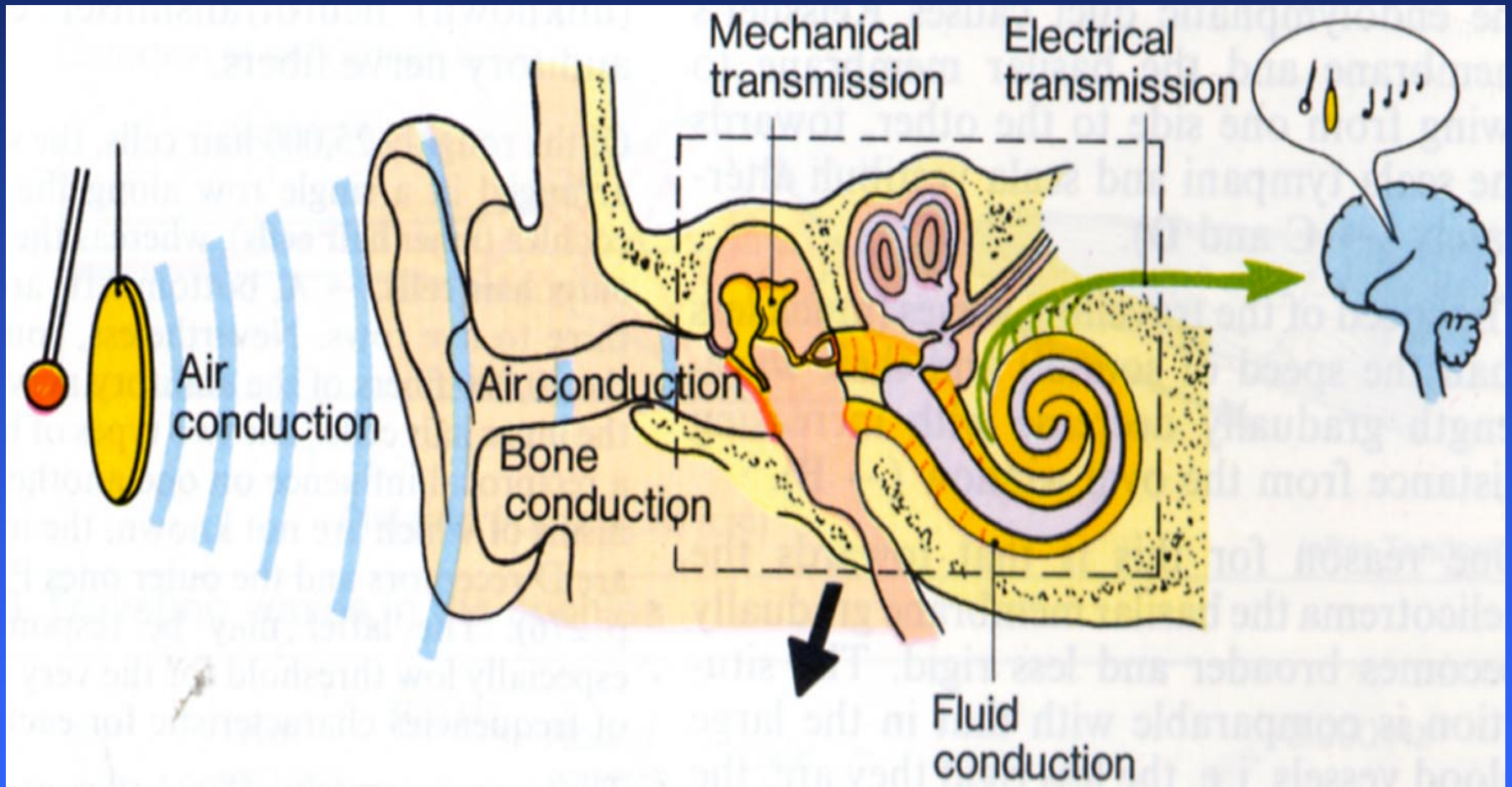
malleus

incus

Round window

Tympanic Membrane

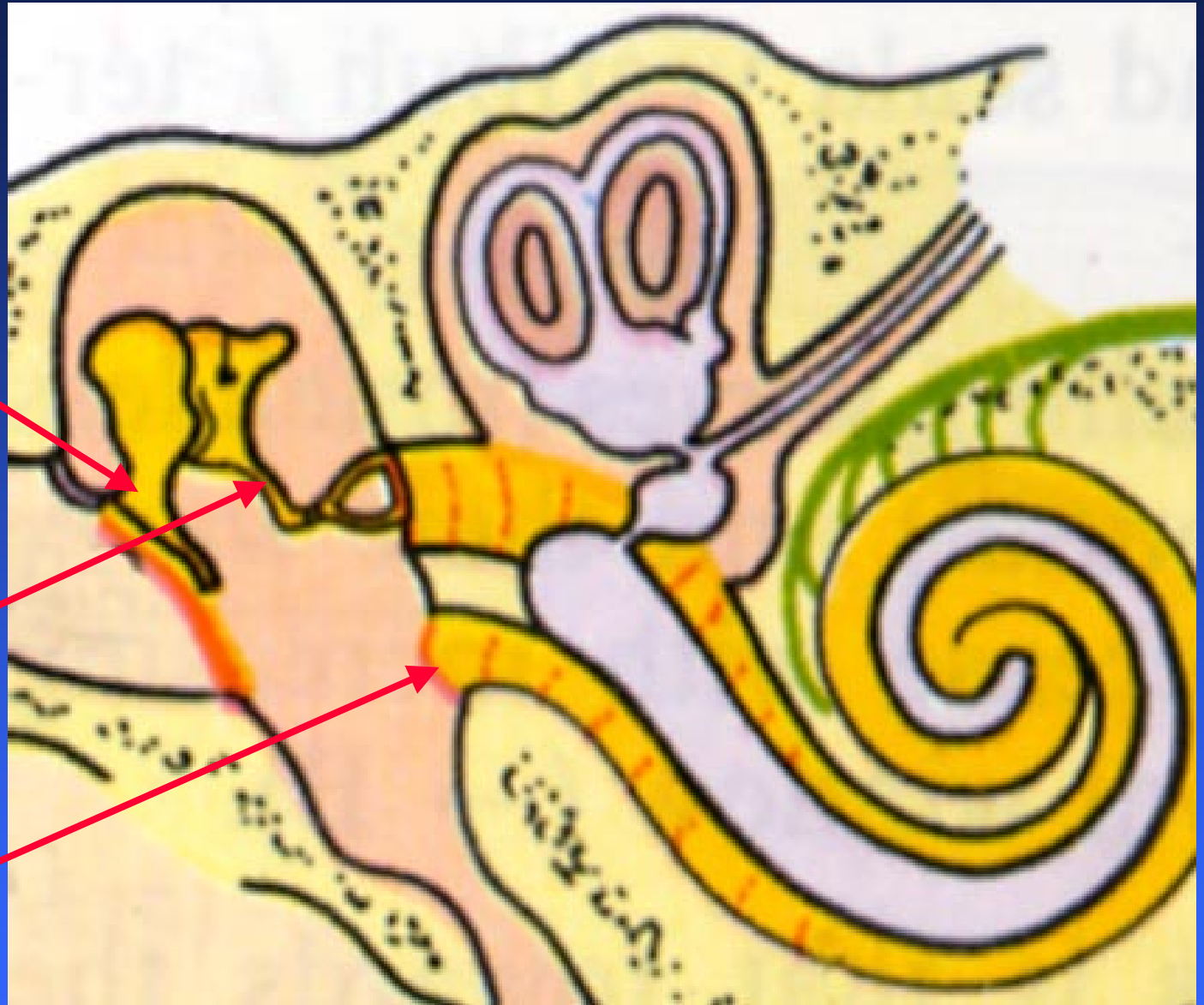The ear



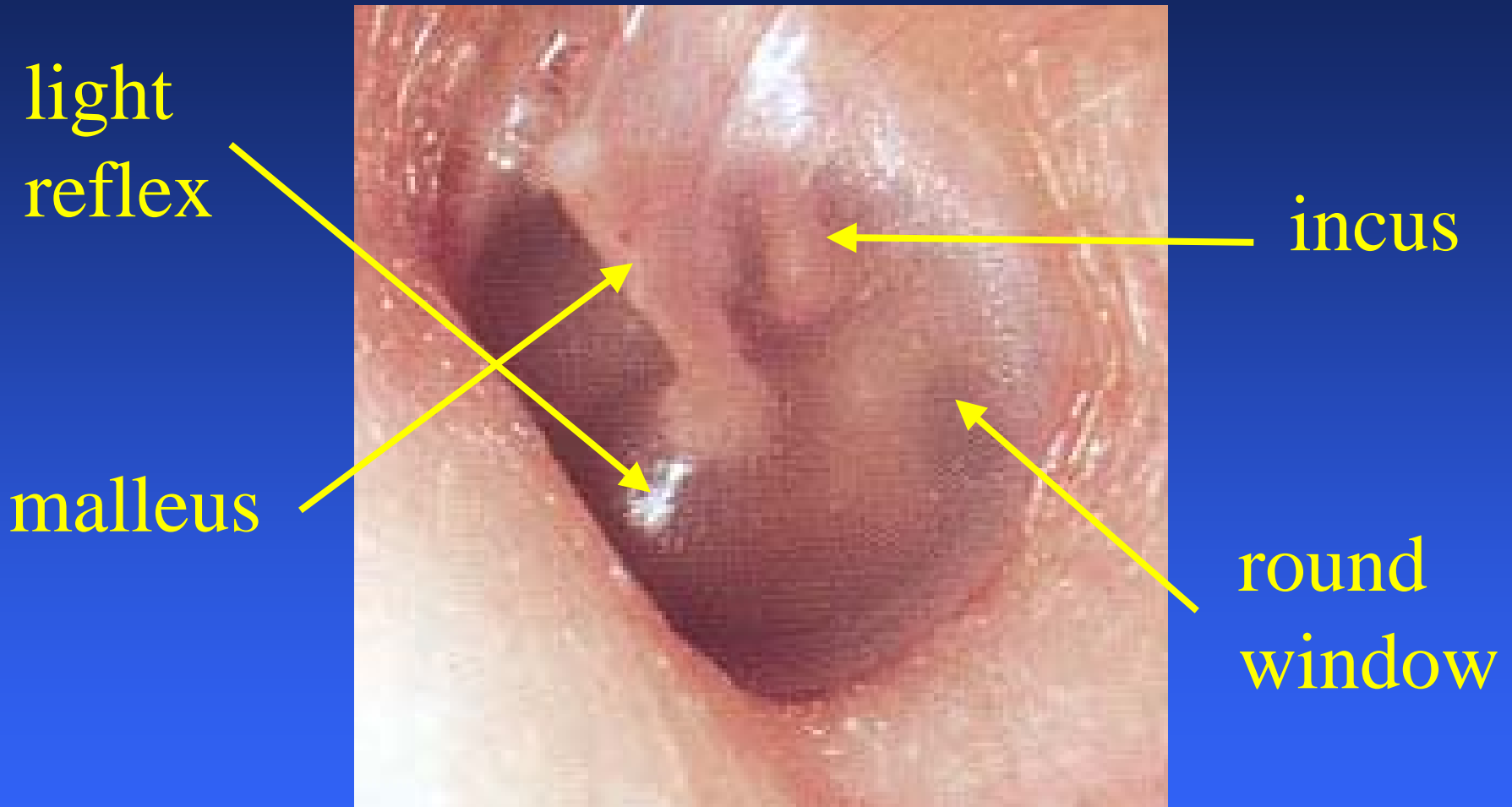
malleus

incus

round
window



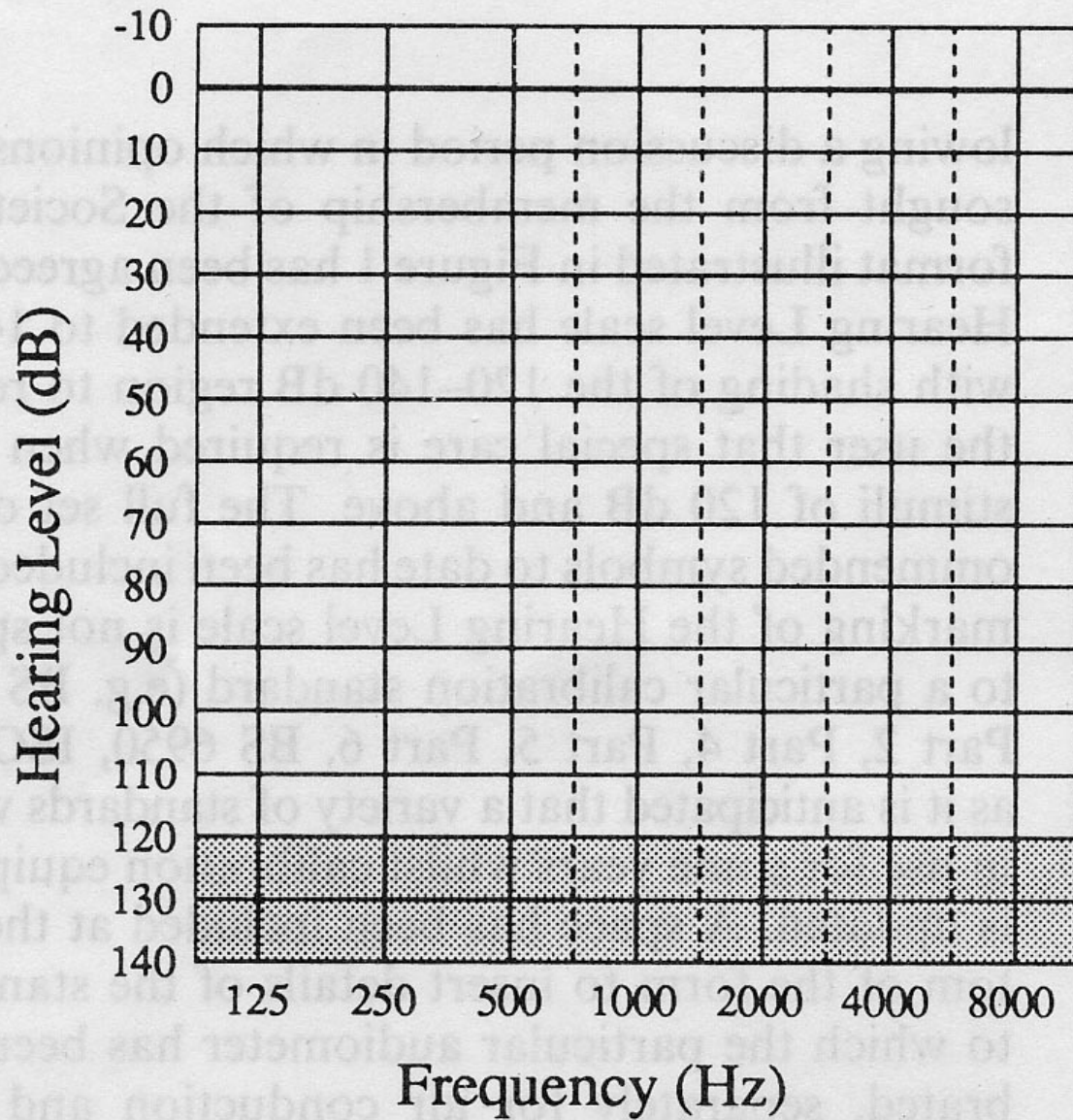
Auriscope Examination




Tympanic Membrane

TOPICS

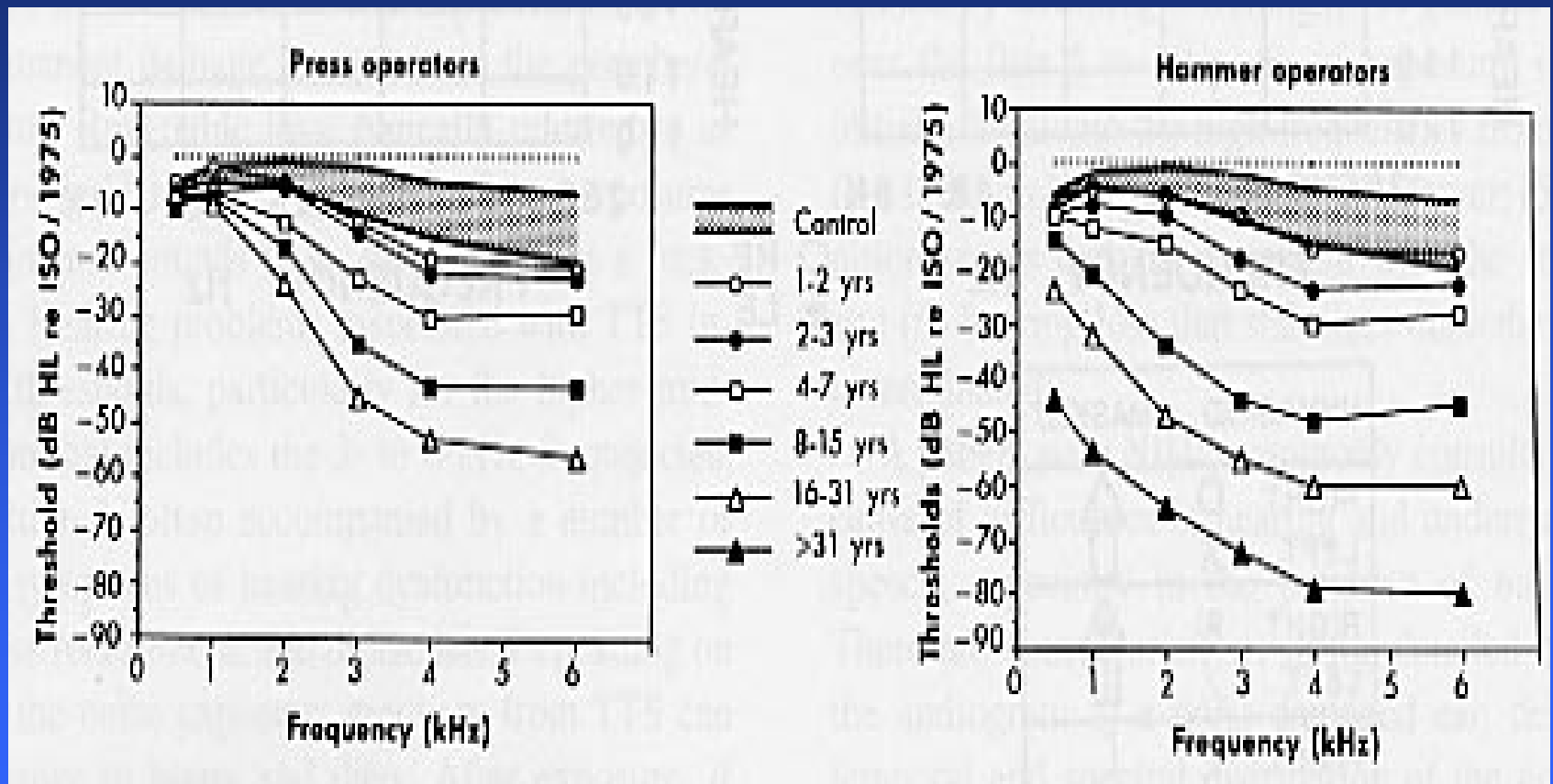
- TAKING A HISTORY
- (EXAMINATION)
- AUDIOGRAMS & HEARING LOSS
- CHRONIC EAR DISEASE
- VERTIGO
- TINNITUS
- GLUE EAR (TARGET STUDY)
- RHINITIS / SINUSITIS
- NECK & THROAT SYMPTOMS
 - HOARSE VOICE
 - DYSPHAGIA
 - THYROID / NECK LUMP
- ANYTHING ELSE



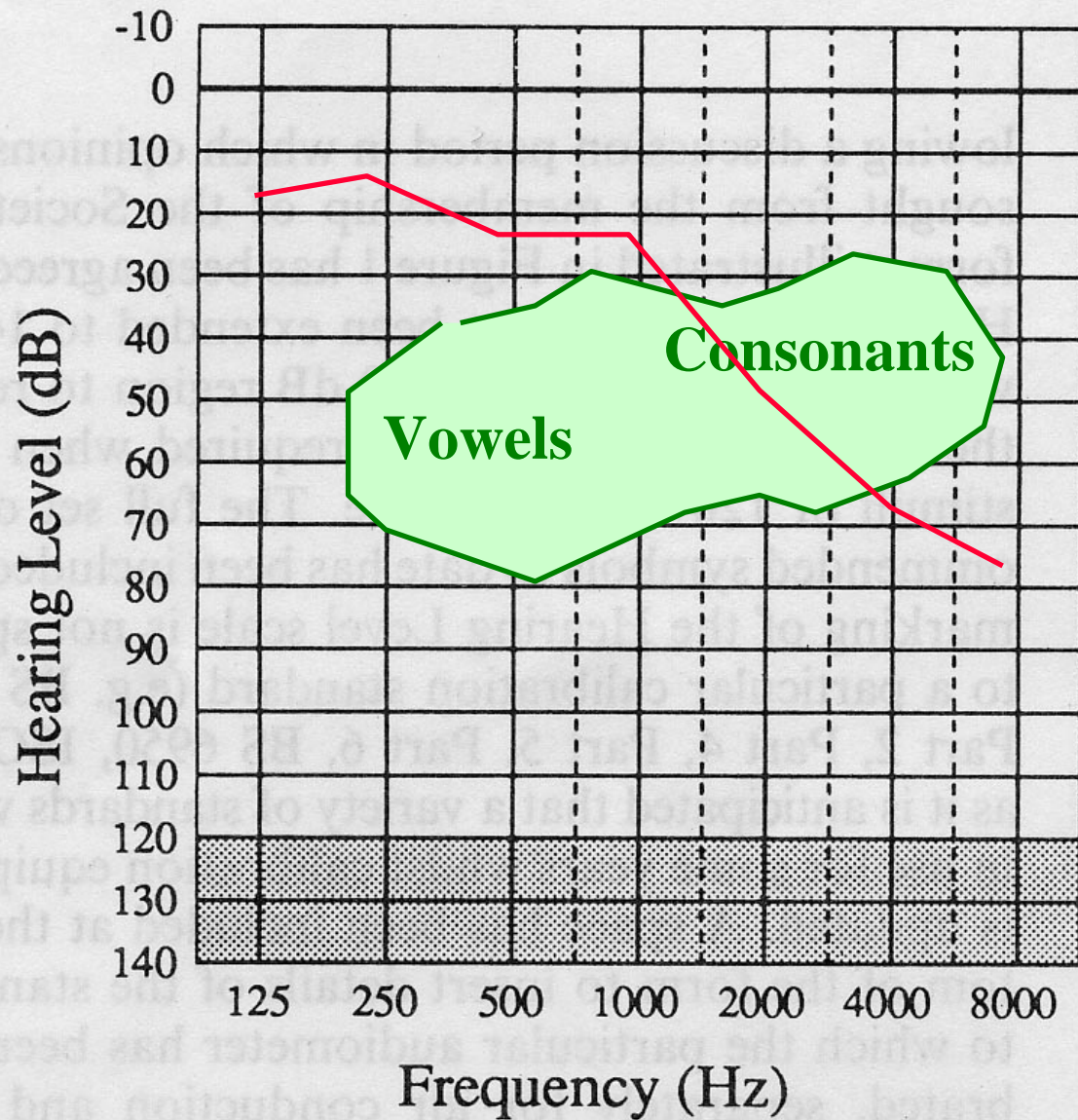
HEARING DISABILITY



NIHL - Audiological findings



High frequency hearing loss



High frequency hearing loss

___e__ _a__ _a__
_a__ o__ ___e__ _a__

High frequency hearing loss

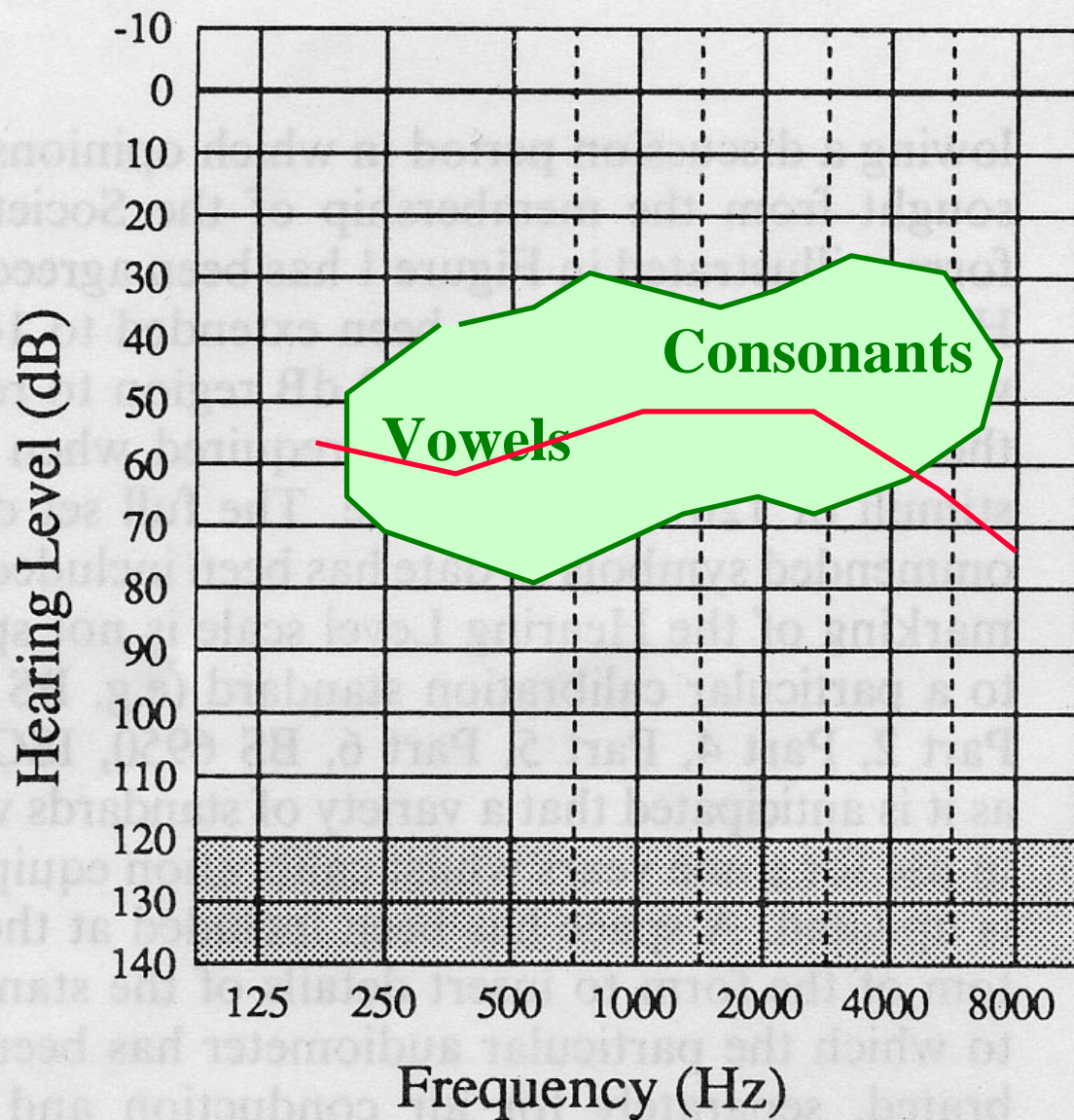
th_ f_ t c_ t
s_ t _n th_ m_ t

High frequency hearing loss

**the fat cat
sat on the mat**

Disability
issues

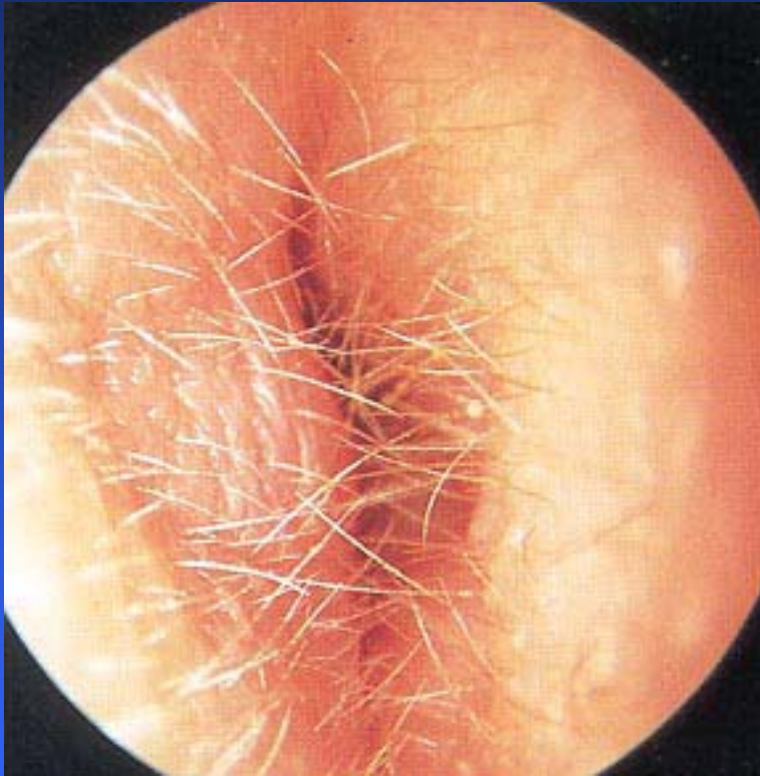Moderate
hearing loss



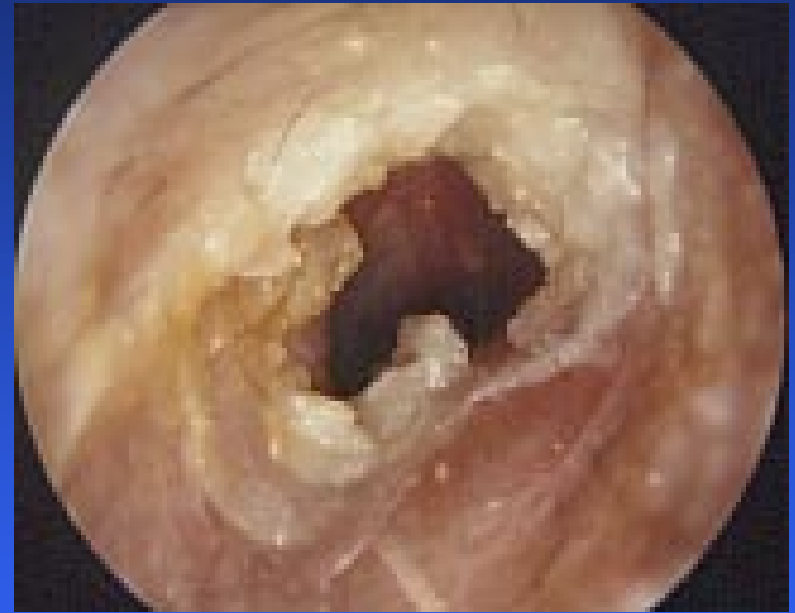TOPICS

- TAKING A HISTORY
- (EXAMINATION)
- AUDIOGRAMS & HEARING LOSS
- CHRONIC EAR DISEASE
- VERTIGO
- TINNITUS
- GLUE EAR (TARGET STUDY)
- RHINITIS / SINUSITIS
- NECK & THROAT SYMPTOMS
 - HOARSE VOICE
 - DYSPHAGIA
 - THYROID / NECK LUMP
- ANYTHING ELSE

Otitis externa



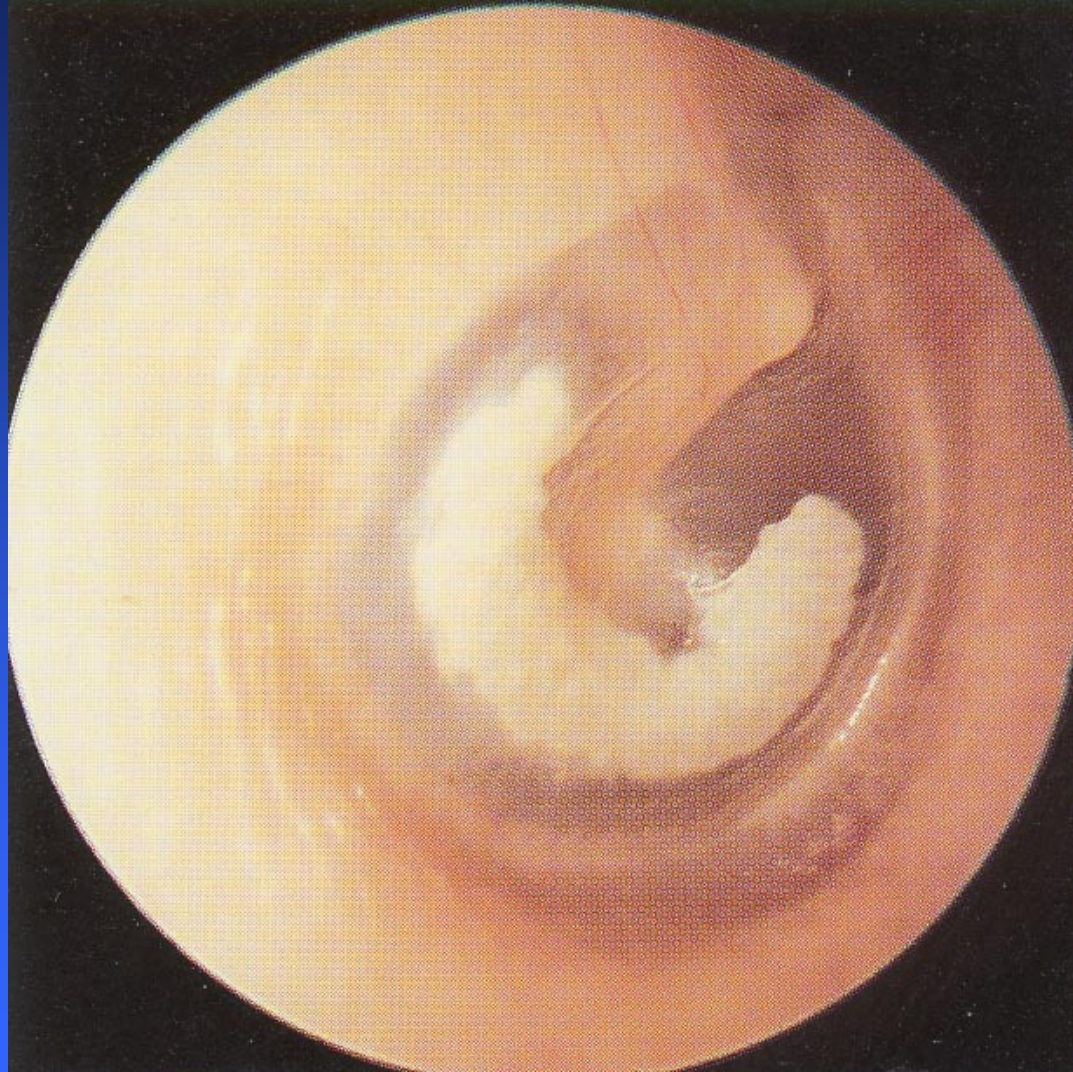
Wicks



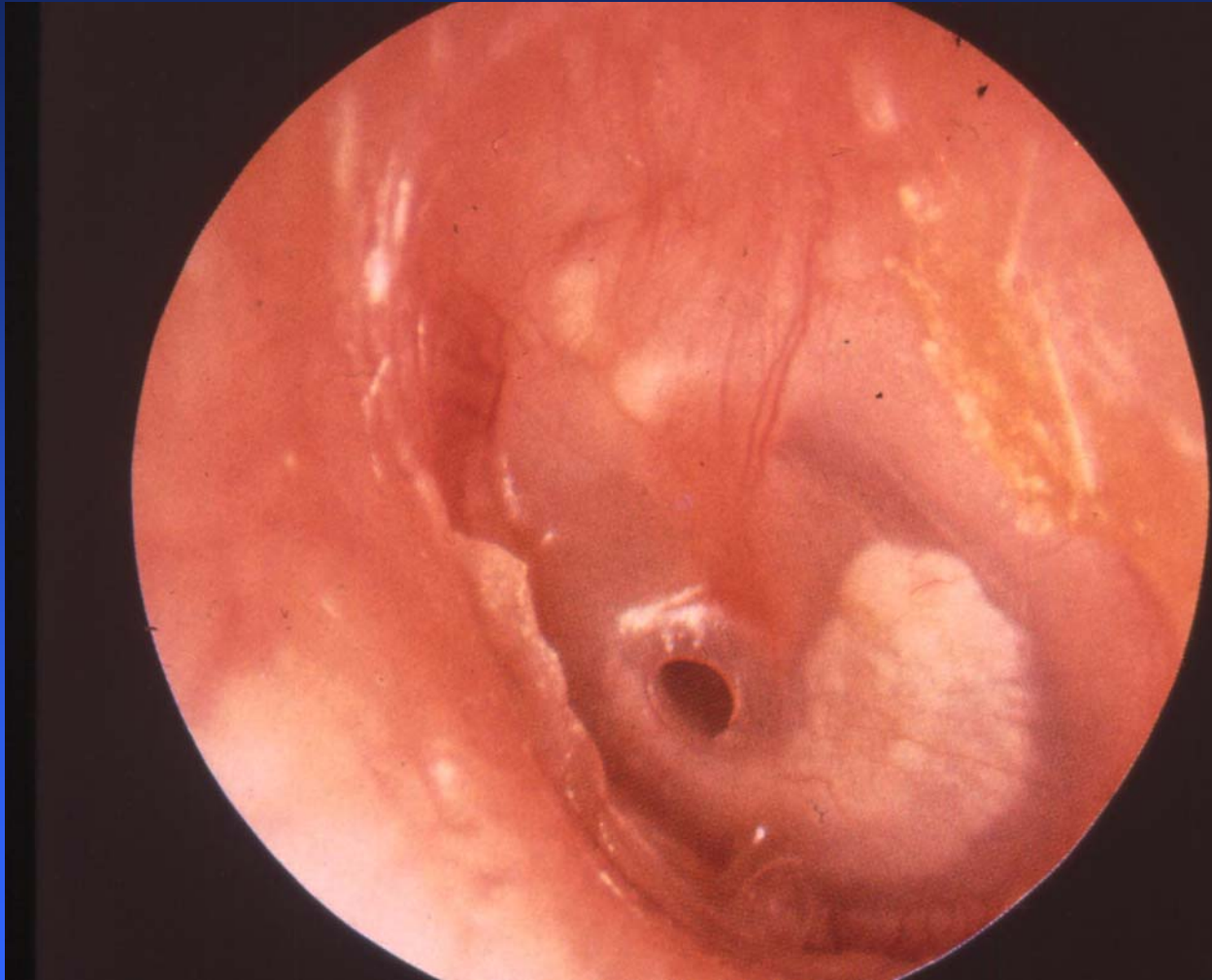
Drops / Spray

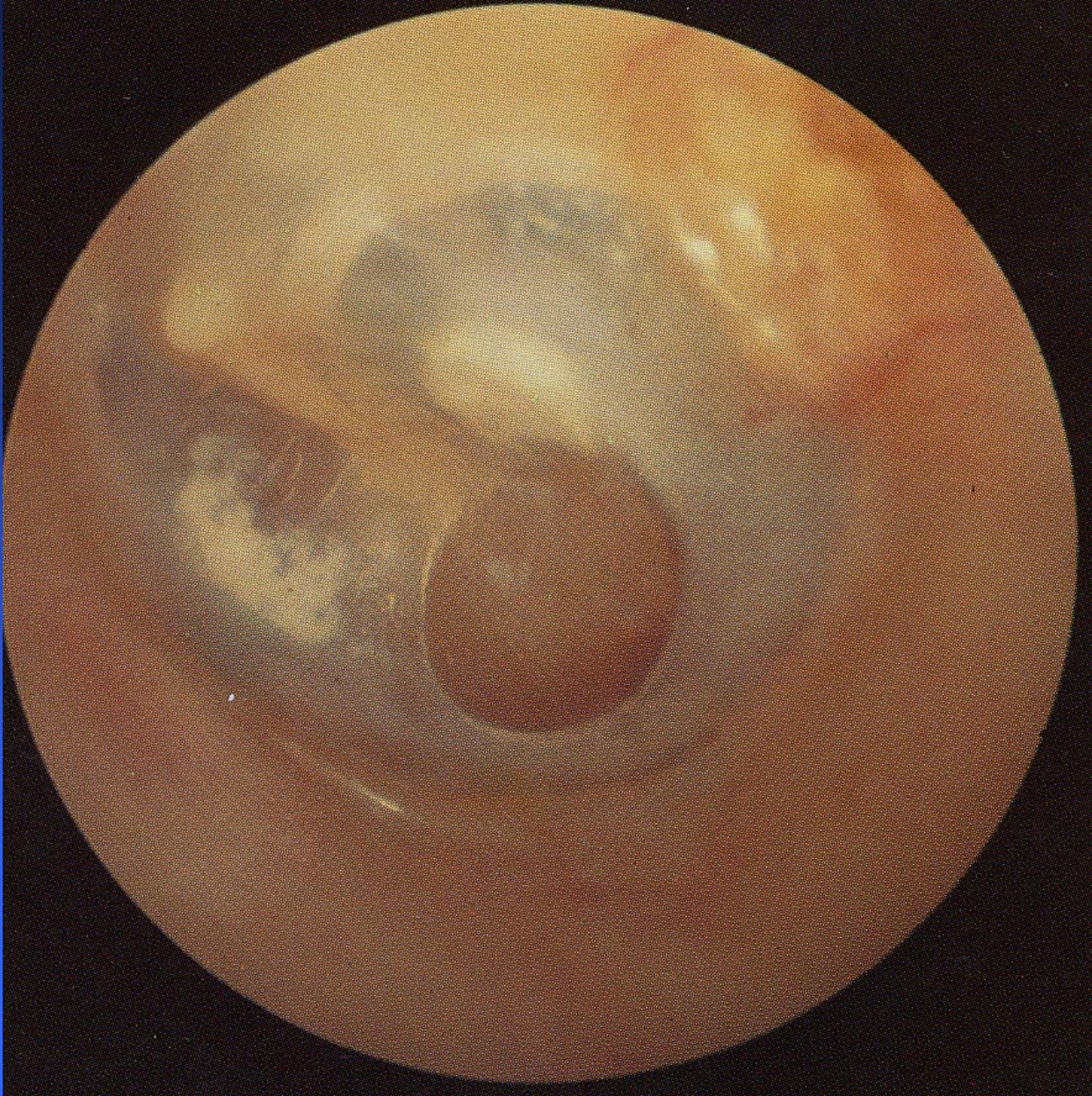
Regular toilet

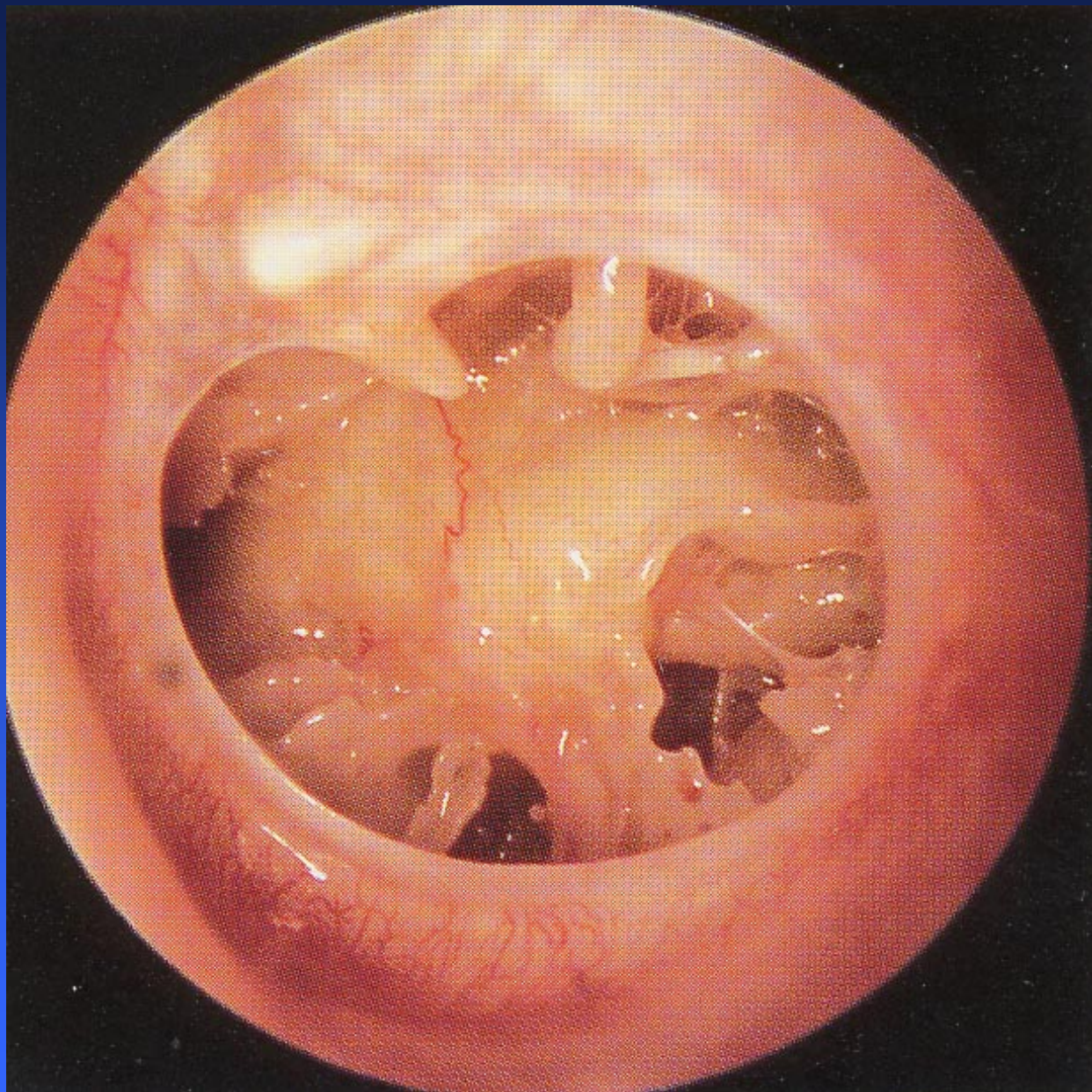
Chronic Ear Disease

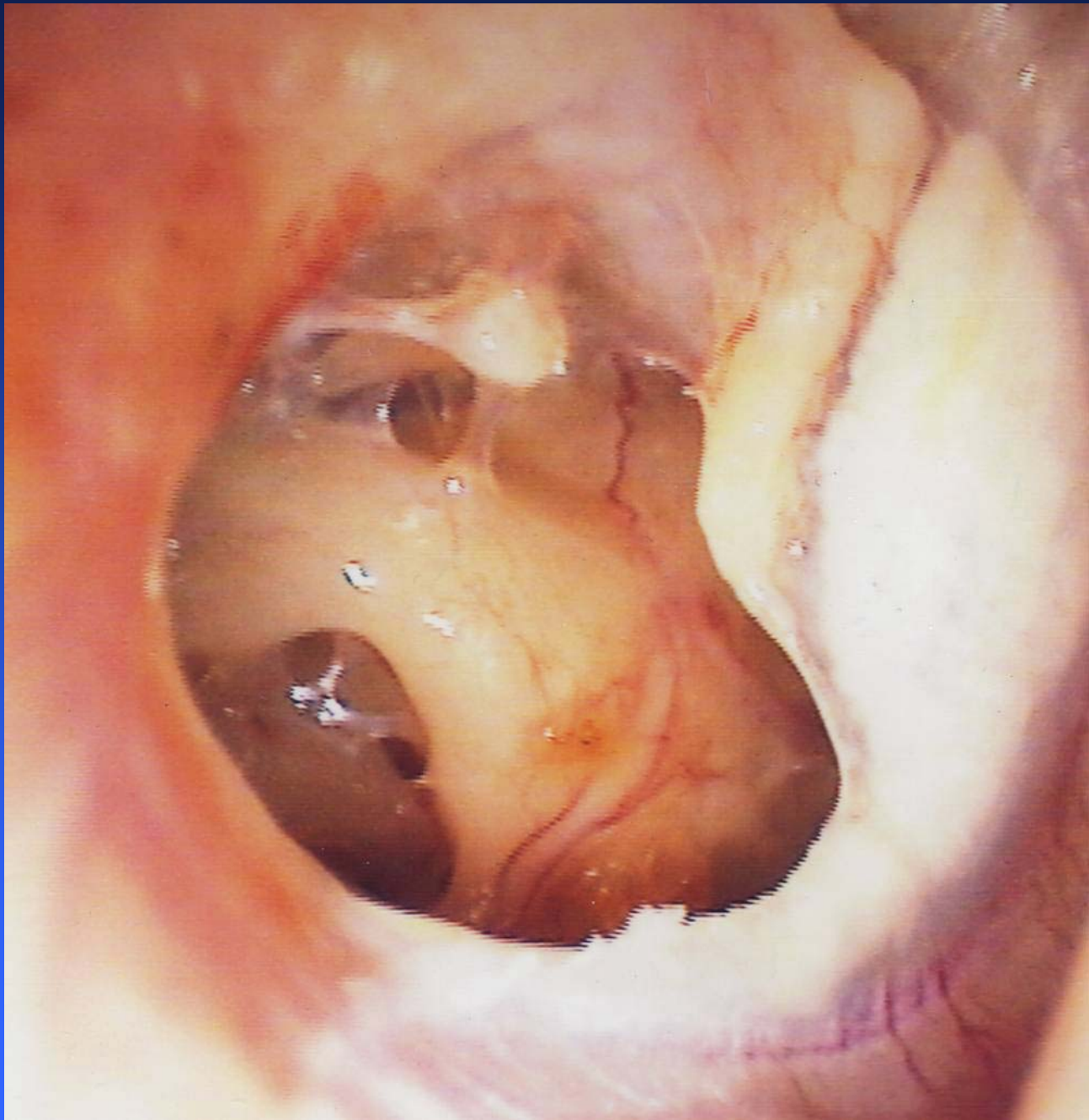


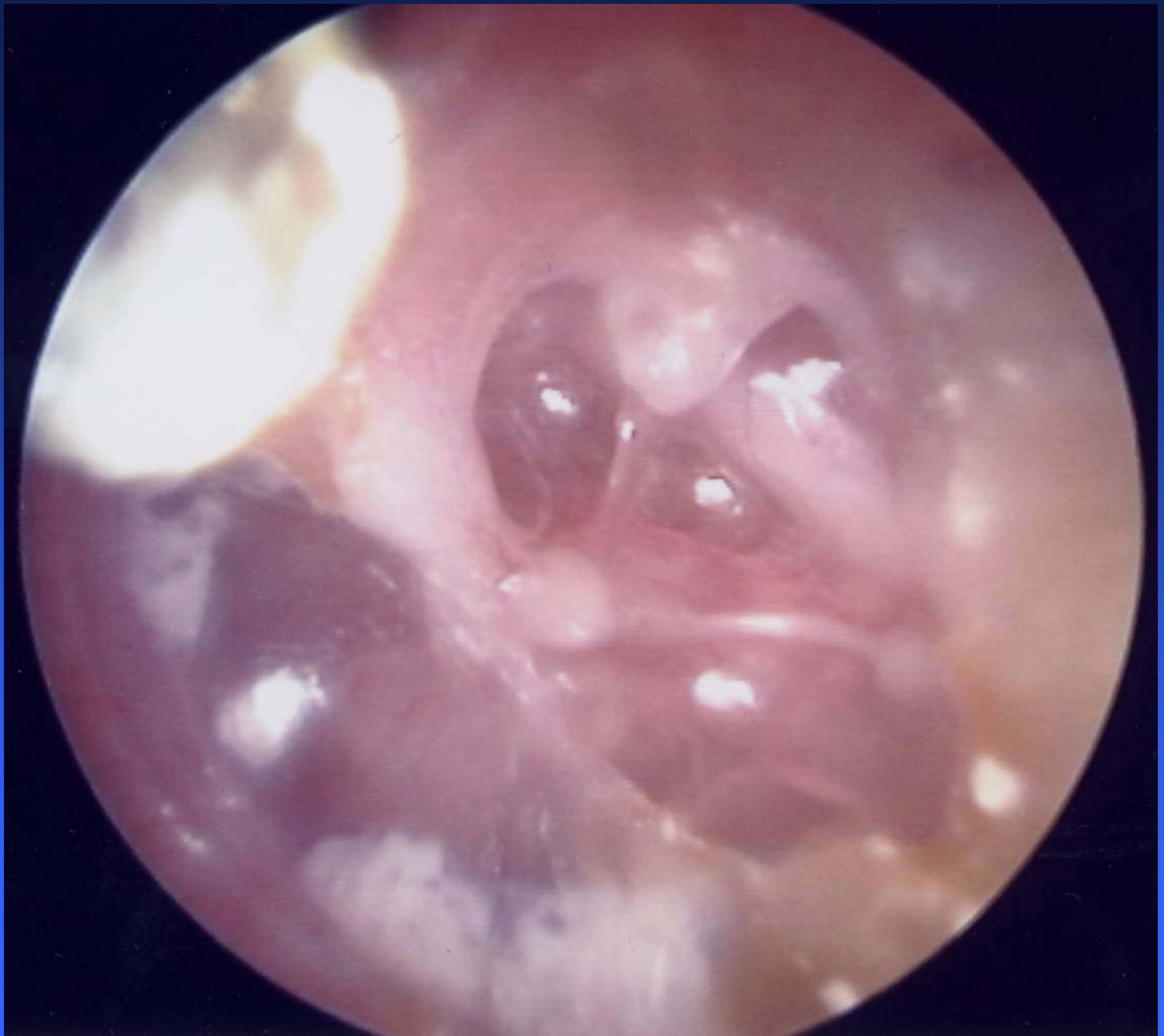
Chronic Ear Disease

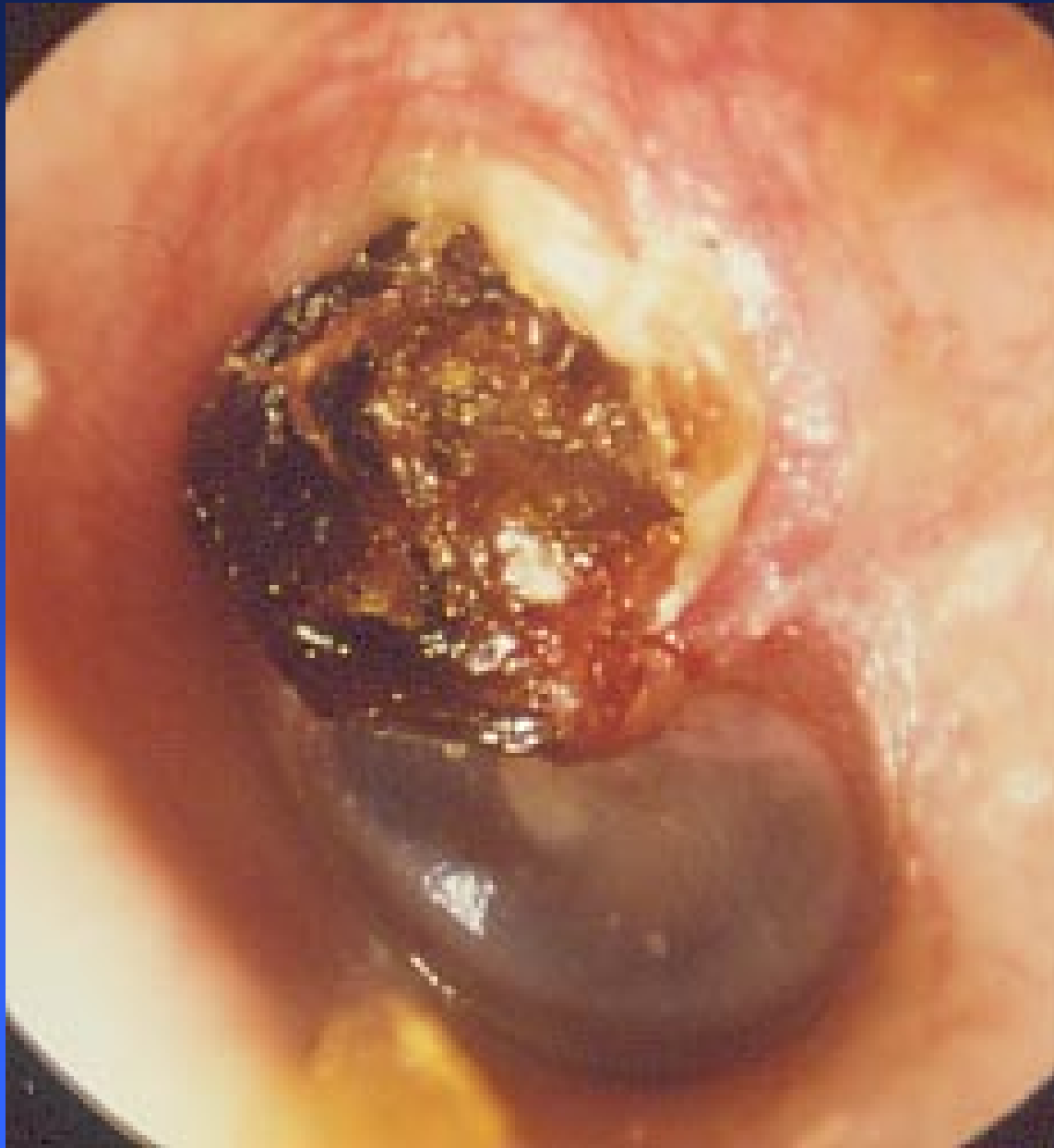








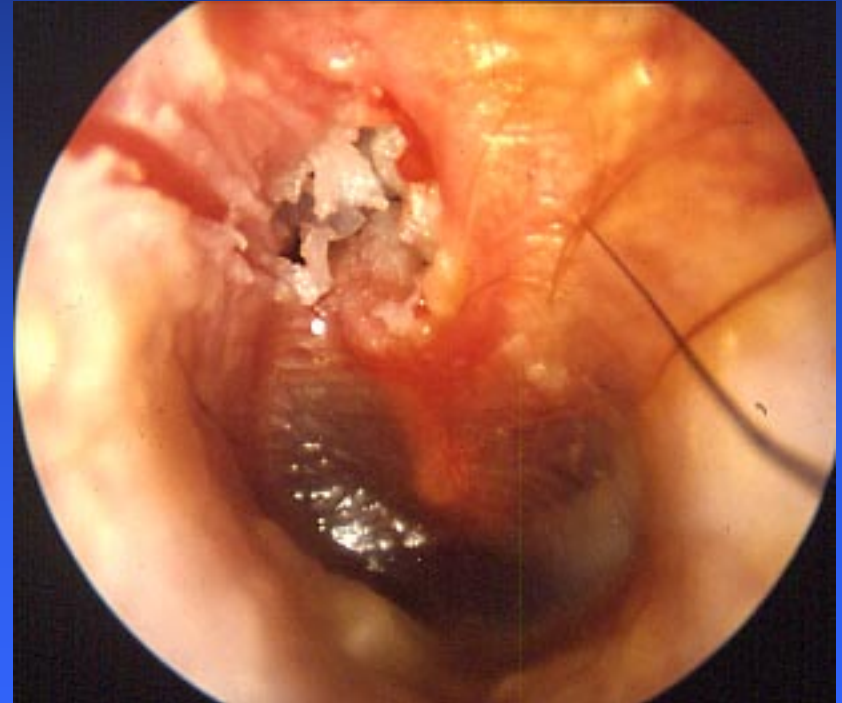
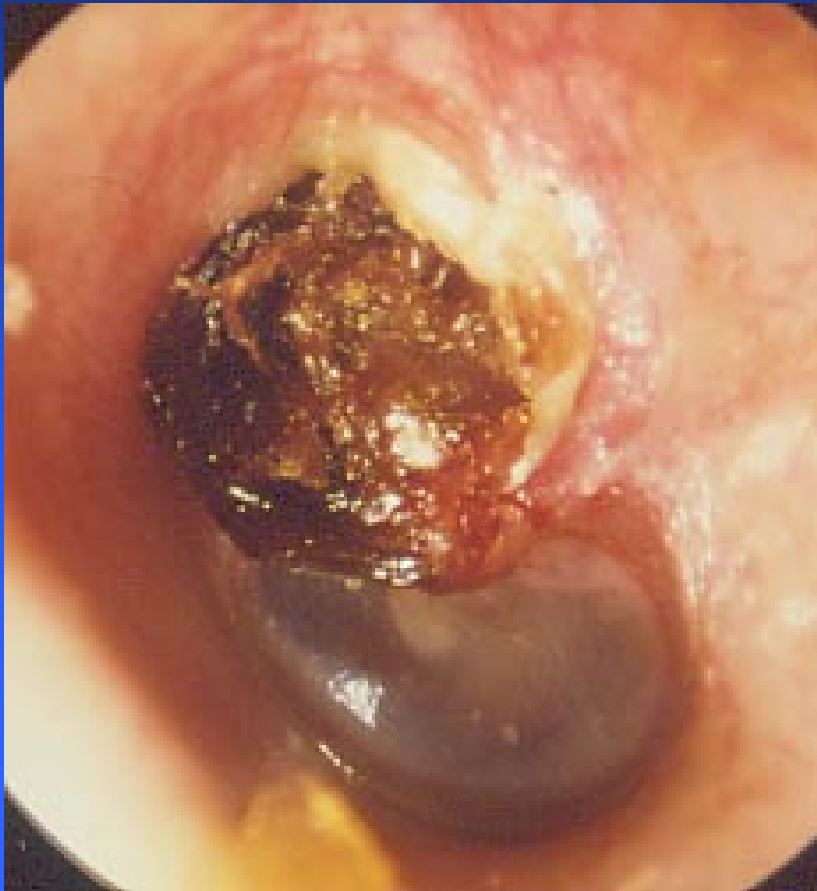




Cholesteatoma

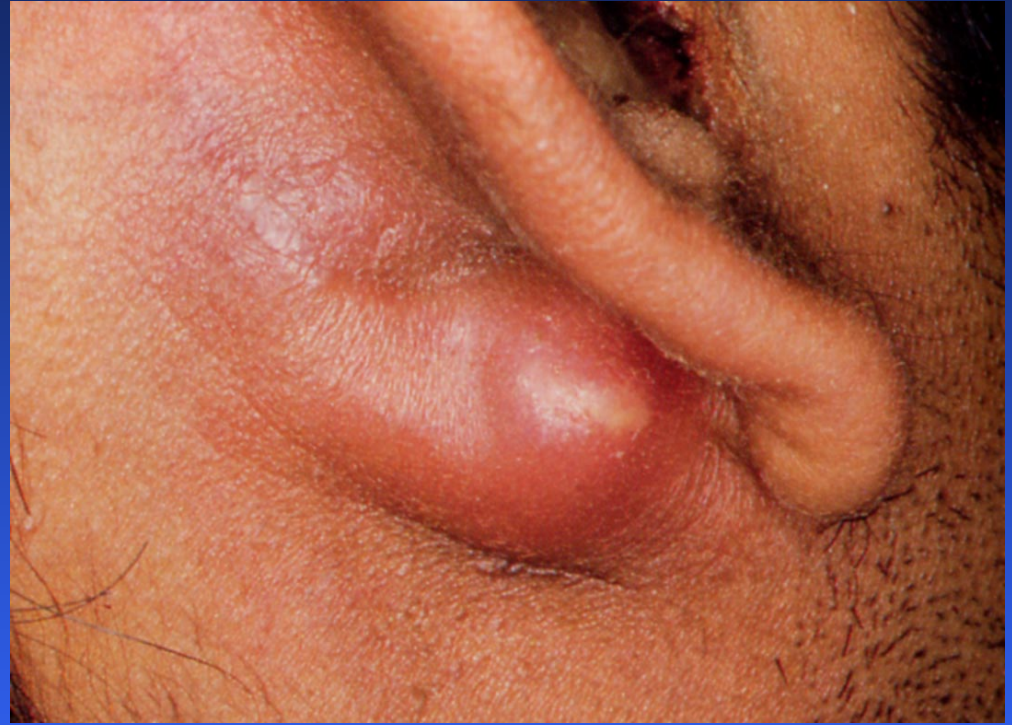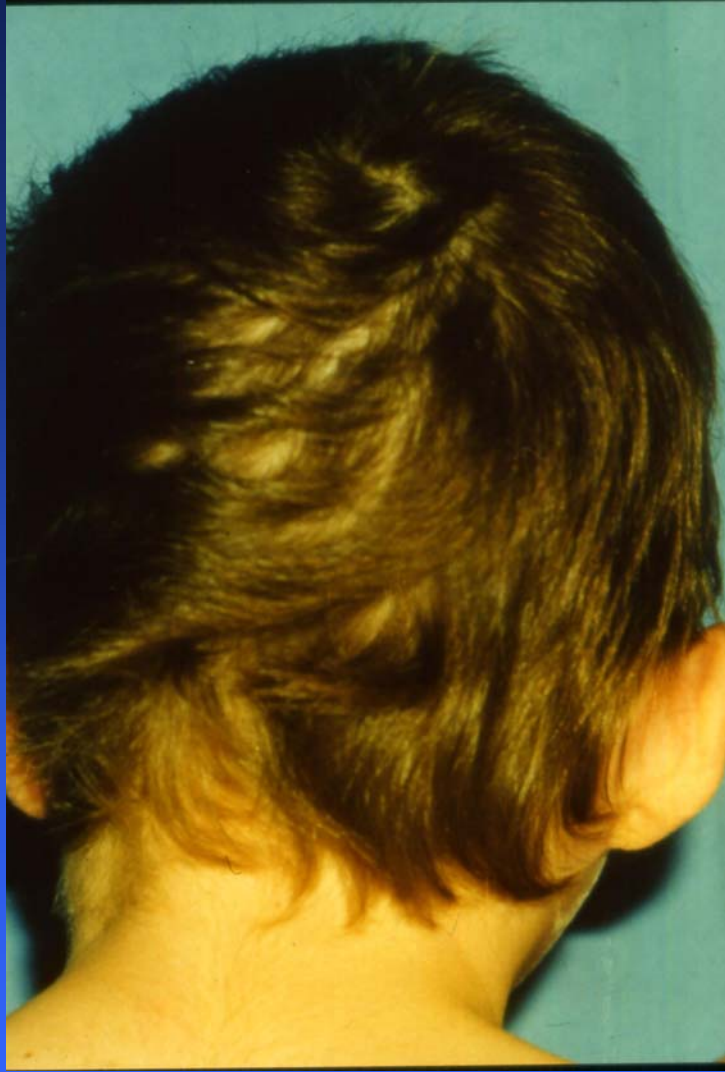“skin in the wrong place”

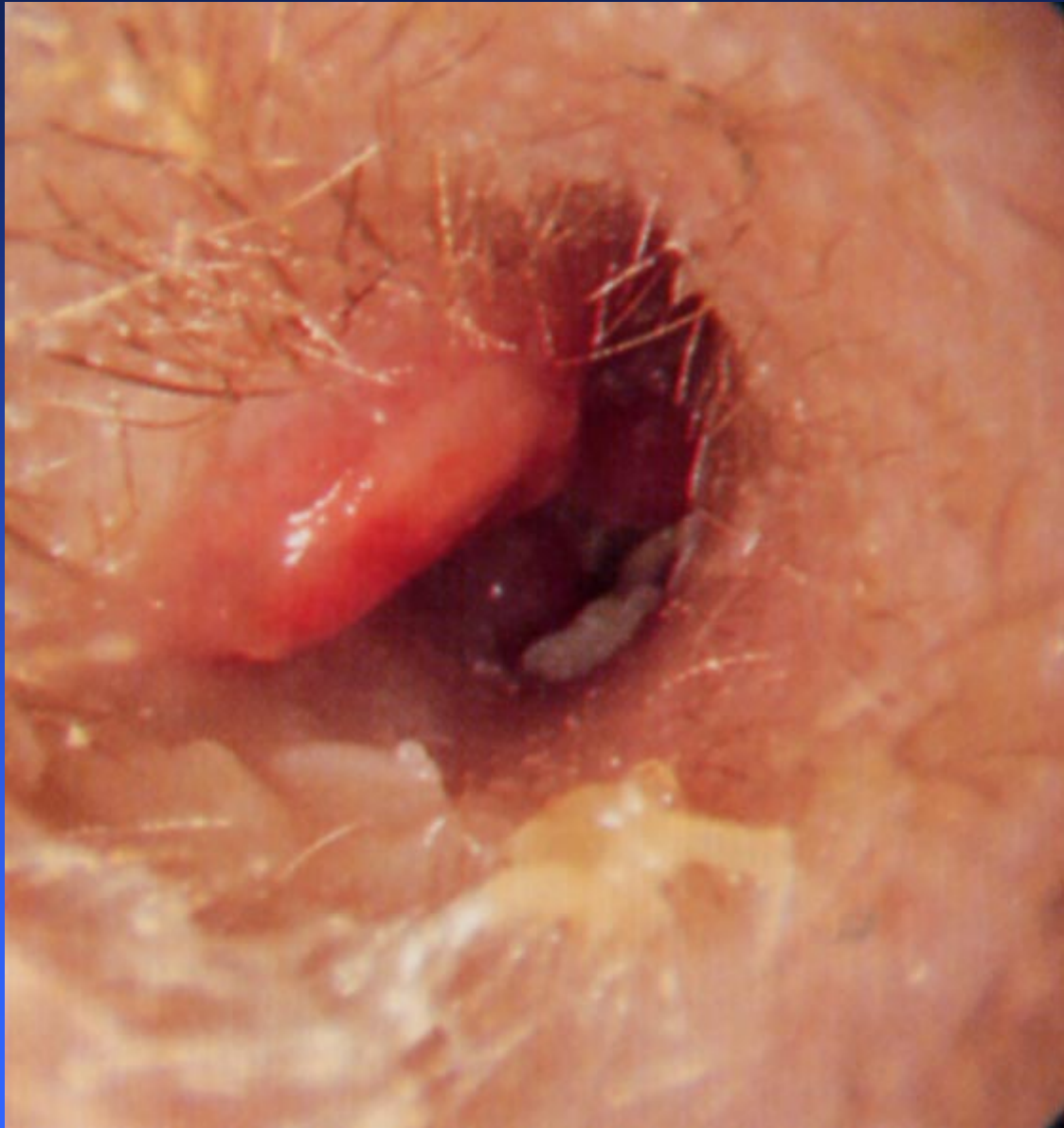Cholesteatoma – diagnosis (can be difficult)

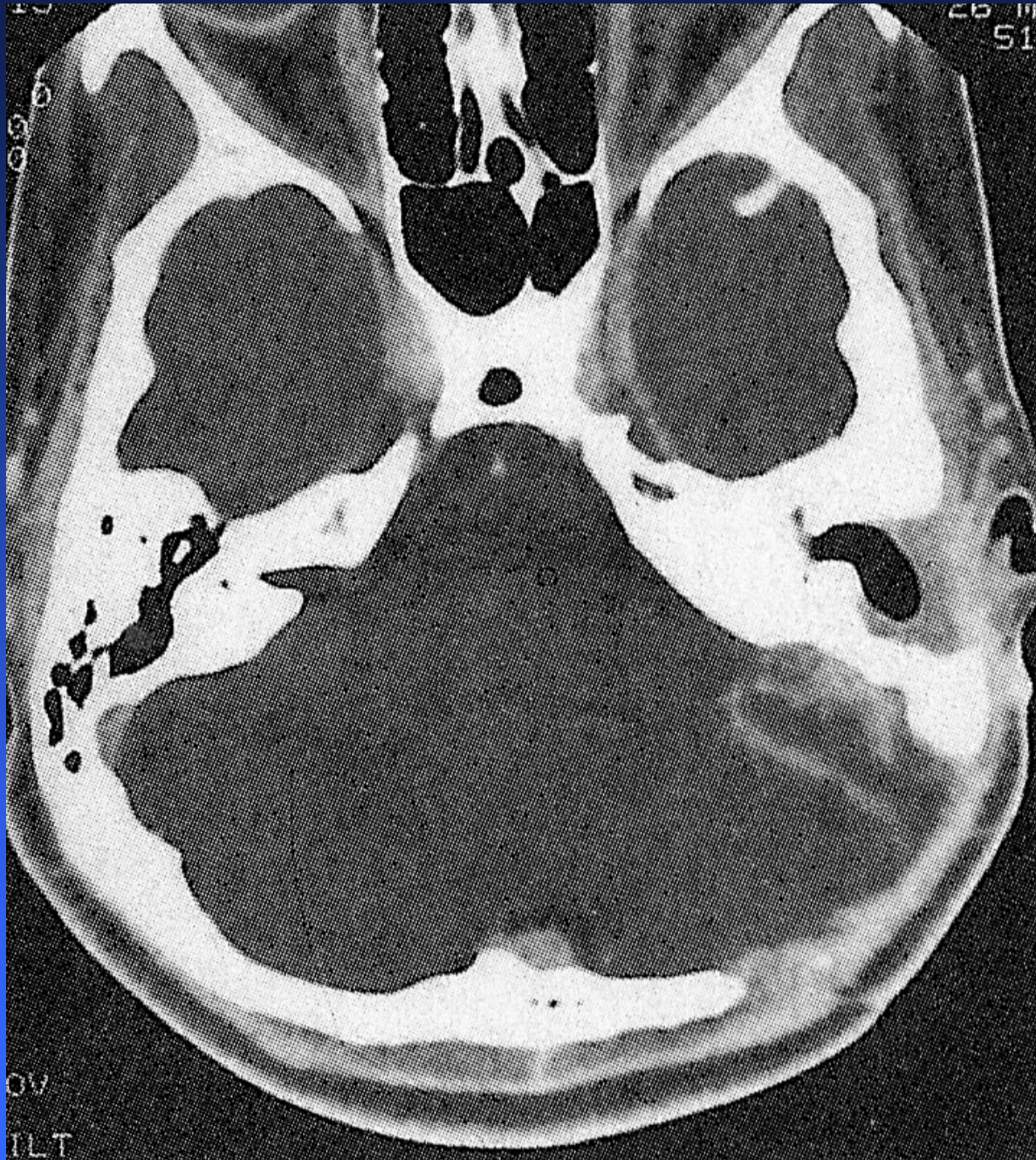


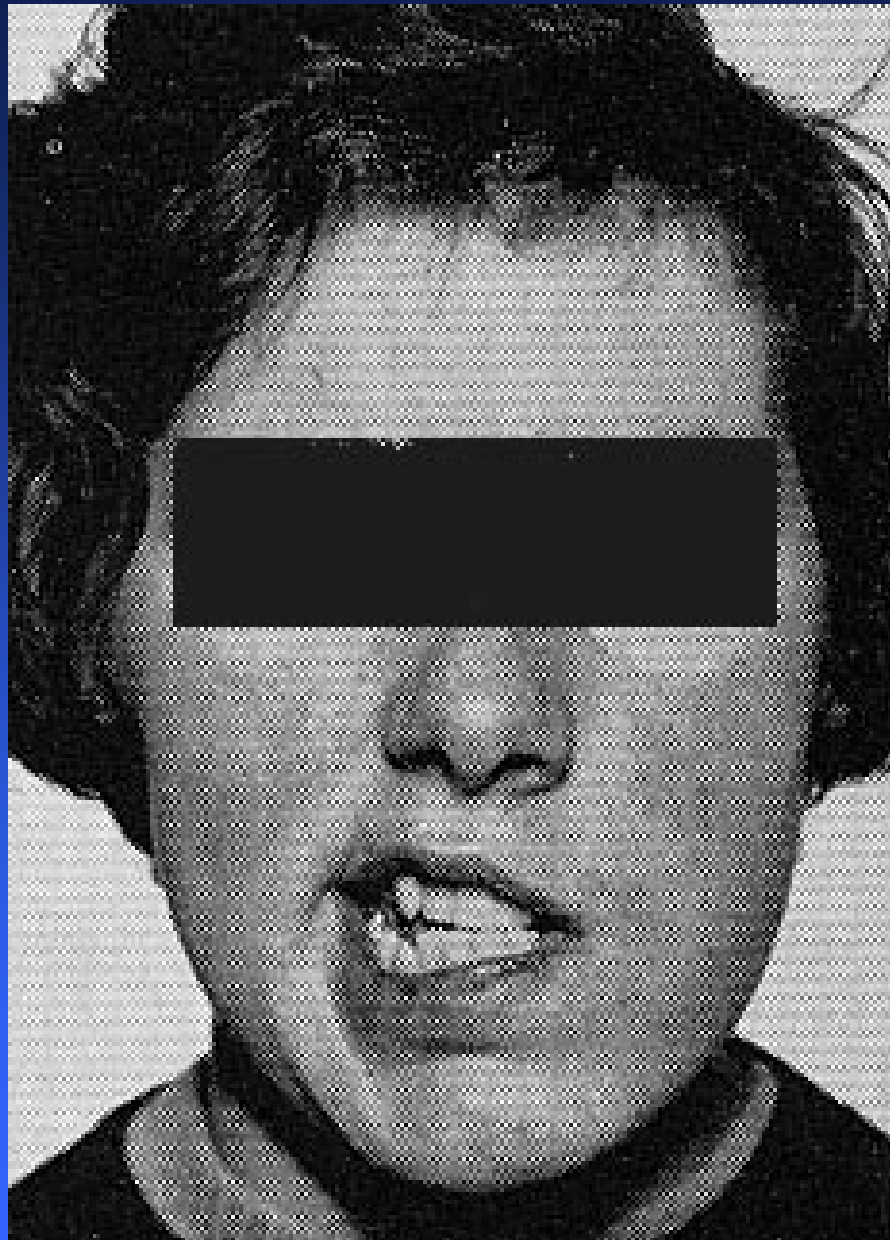Complications of middle ear disease











Superiorly (intracranial)

Brain abscess

Extradural abscess

Meningitis

Middle ear

Deafness

Ossicular damage

Medially

Labyrinthitis

Nerve VII paralysis

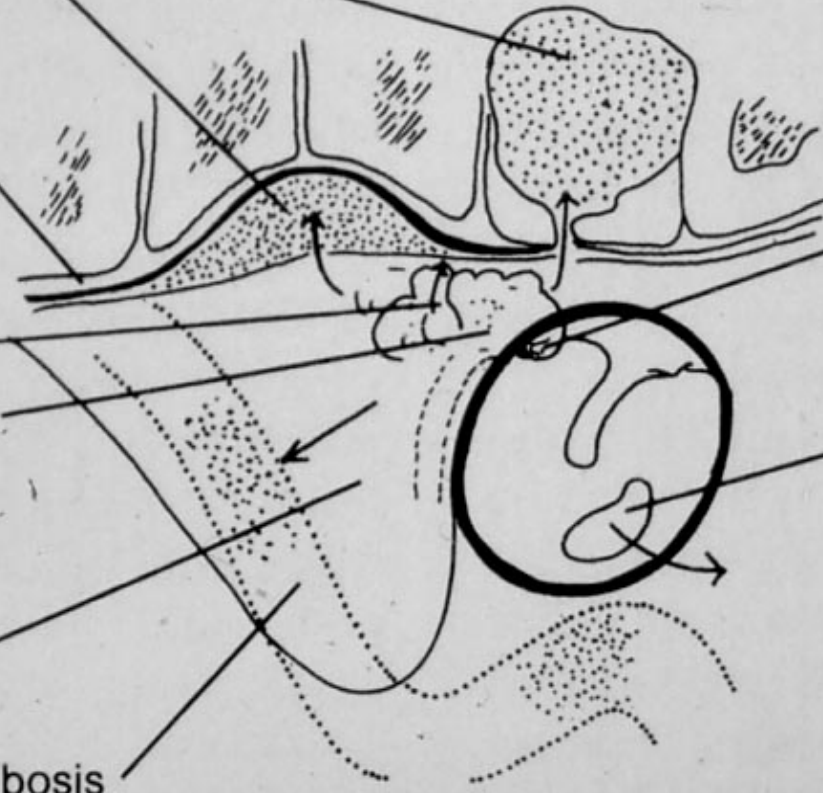
Laterally

Perforation and pus
in the ear canal

Posteriorly

Mastoiditis

Lateral sinus thrombosis



TOPICS

- TAKING A HISTORY
- (EXAMINATION)
- AUDIOGRAMS & HEARING LOSS
- CHRONIC EAR DISEASE
- VERTIGO
- TINNITUS
- GLUE EAR (TARGET STUDY)
- RHINITIS / SINUSITIS
- NECK & THROAT SYMPTOMS
 - HOARSE VOICE
 - DYSPHAGIA
 - THYROID / NECK LUMP
- ANYTHING ELSE

What is Vertigo



Vertigo

- Sensation of rotation
- Not ‘unsteadiness’
- Not ‘lightheadedness’
- History is key

History is key



good

? Symptoms with time



bad

good



- Lasts hours
- Variable attacks
- Other symptoms
- ? *menieres*



bad

good




Severe initial attack
Slow improvement
? Vestibular
neuro labyrinthitis



bad



good



lasts seconds
related to head posn
? BPPV



bad

Dix Hallpike

- BPPV & Epley manoeuvre

TOPICS

- TAKING A HISTORY
- (EXAMINATION)
- AUDIOGRAMS & HEARING LOSS
- CHRONIC EAR DISEASE
- VERTIGO
- TINNITUS
- GLUE EAR (TARGET STUDY)
- RHINITIS / SINUSITIS
- NECK & THROAT SYMPTOMS
 - HOARSE VOICE
 - DYSPHAGIA
 - THYROID / NECK LUMP
- ANYTHING ELSE

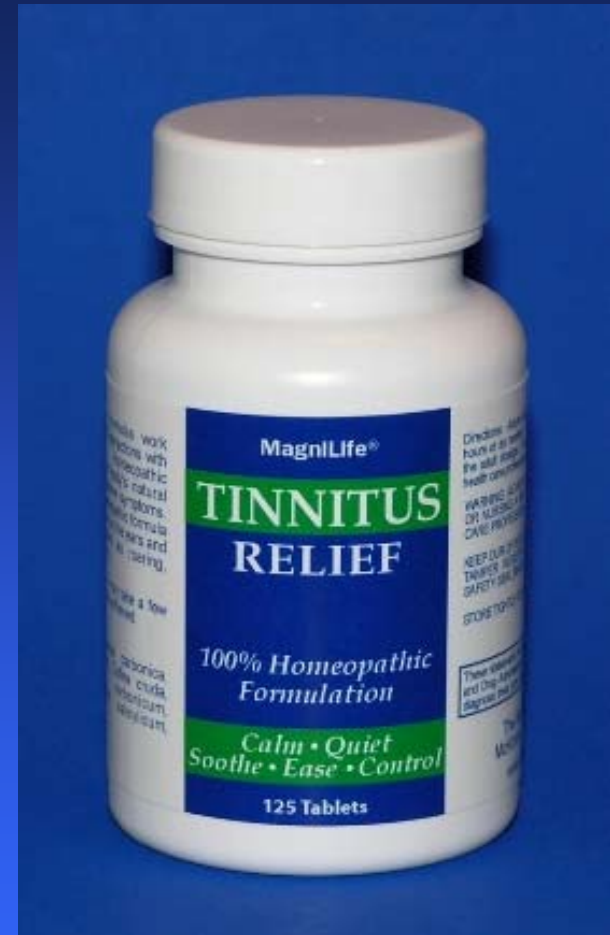

A symptom not a diagnosis

A buzzing in his ears seems to have been the first symptom. The trouble was not at first constant, though the buzzing sometimes drove him into a frenzy.

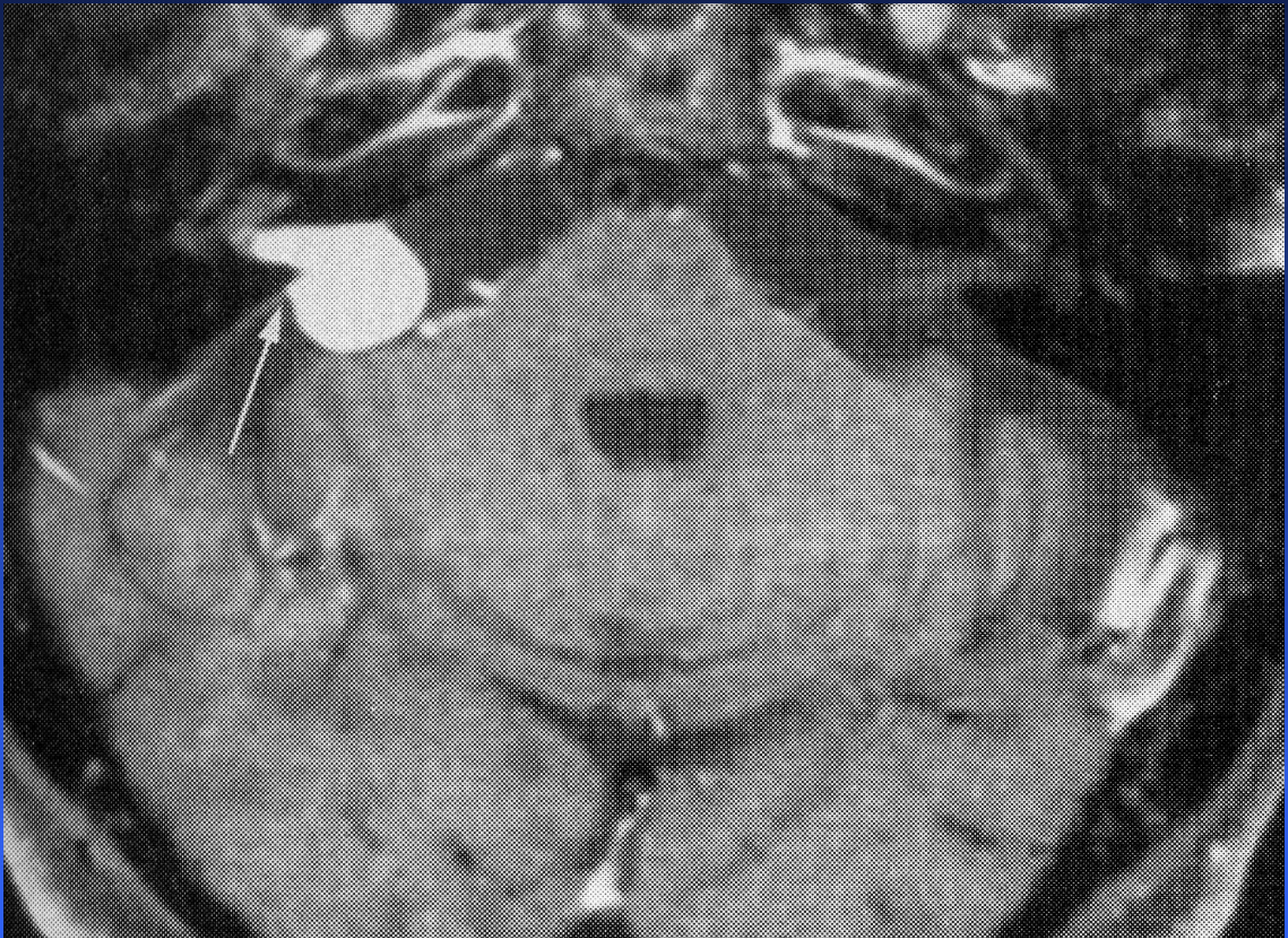
Tinnitus

- Diagnosis explained
- Investigate as appropriate
 - Audio
 - ? MRI
- Treatment options
 - Nil
 - Simple strategies
 - TRT (Tinnitus Retraining Therapy)



Key point

- Persistent unilateral symptoms

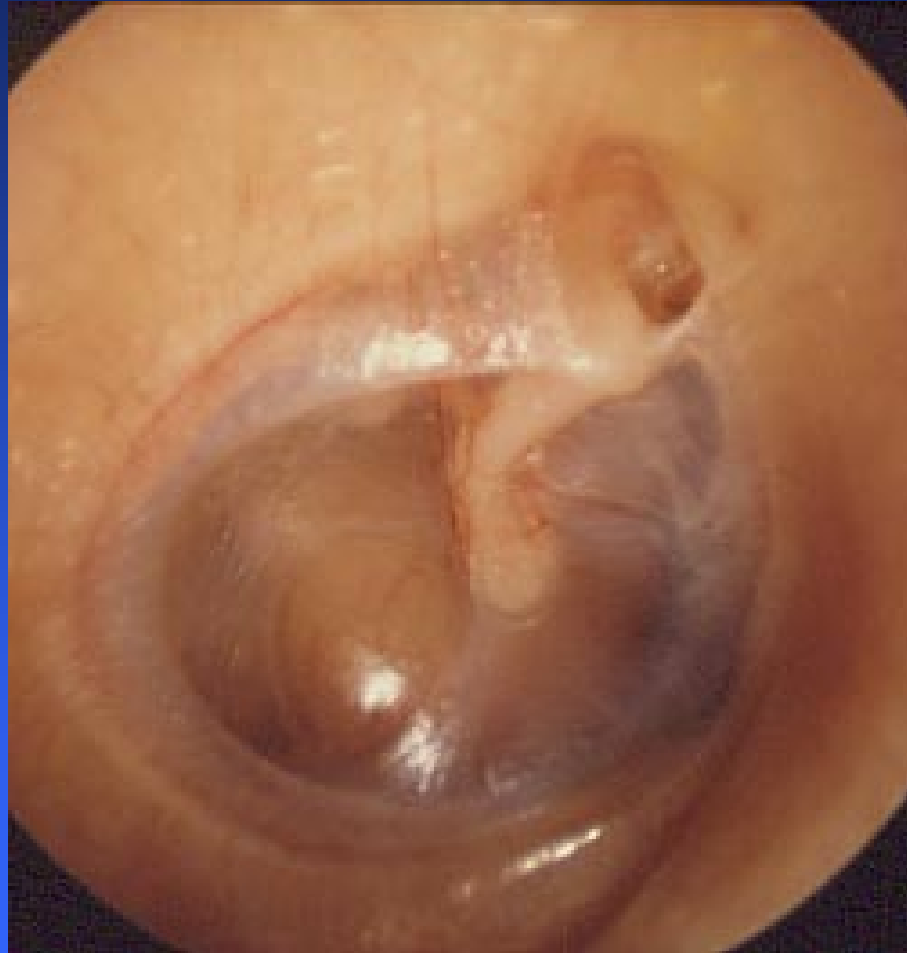


Unilateral hearing loss +/- tinnitus

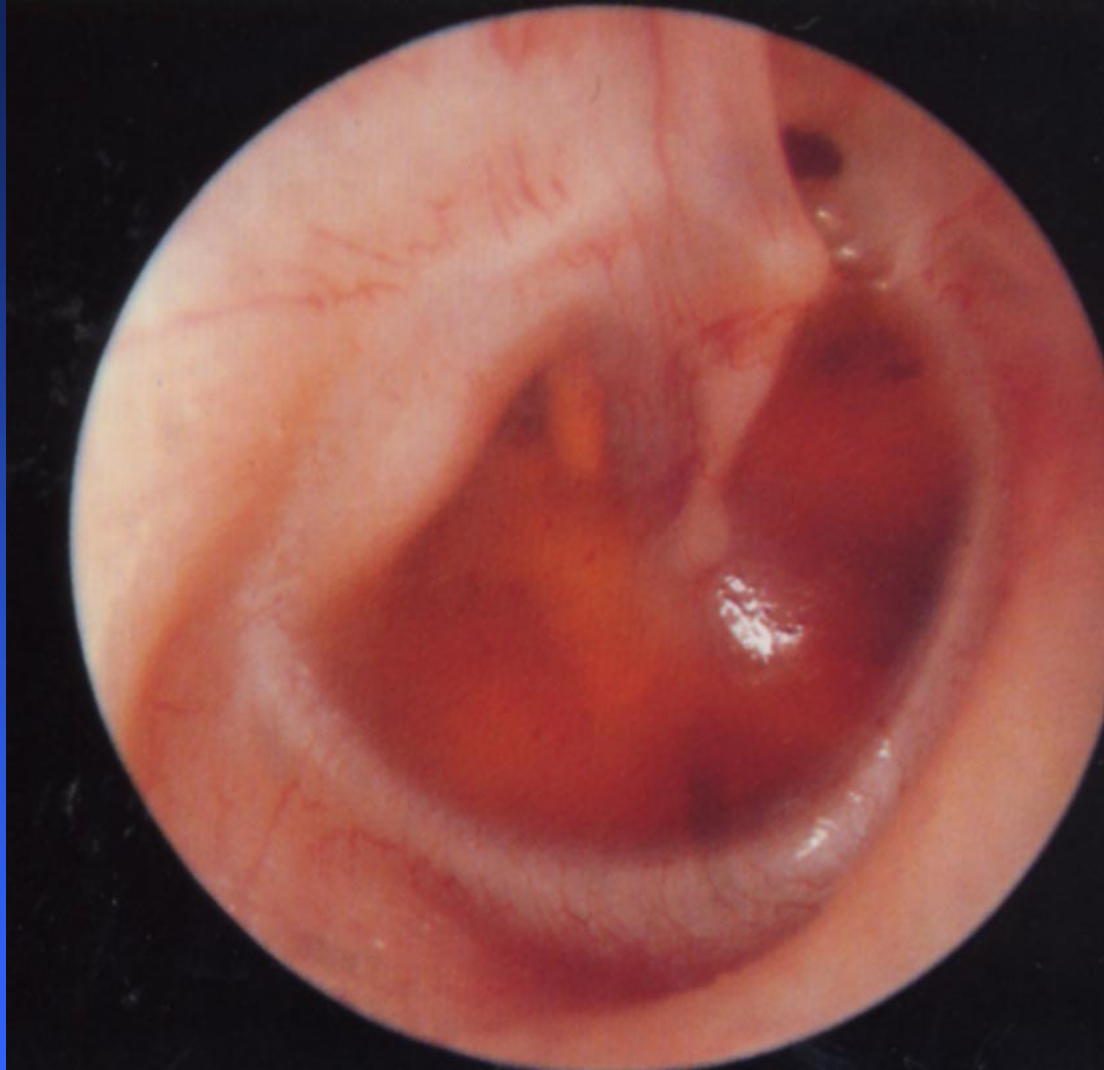
TOPICS

- TAKING A HISTORY
- (EXAMINATION)
- AUDIOGRAMS & HEARING LOSS
- CHRONIC EAR DISEASE
- VERTIGO
- TINNITUS
- GLUE EAR (TARGET STUDY)
- RHINITIS / SINUSITIS
- NECK & THROAT SYMPTOMS
 - HOARSE VOICE
 - DYSPHAGIA
 - THYROID / NECK LUMP
- ANYTHING ELSE

Diagnosing OME



Diagnosing OME



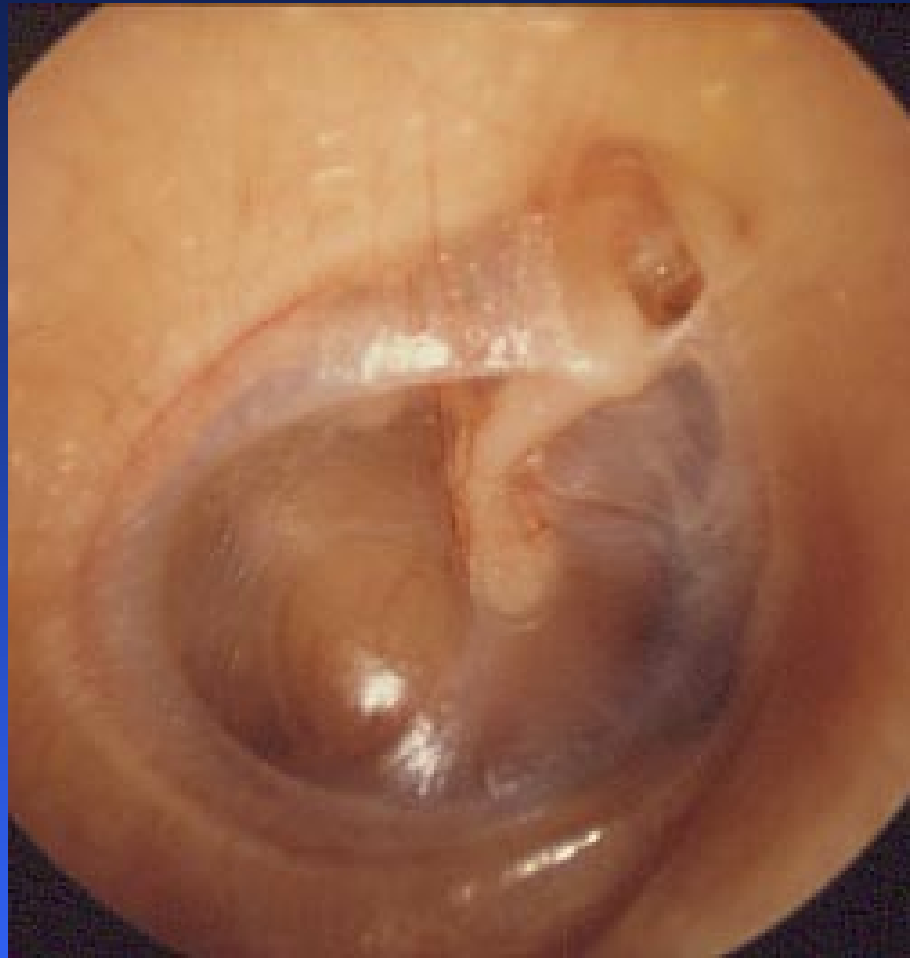
Audio + tymps

Treating OME

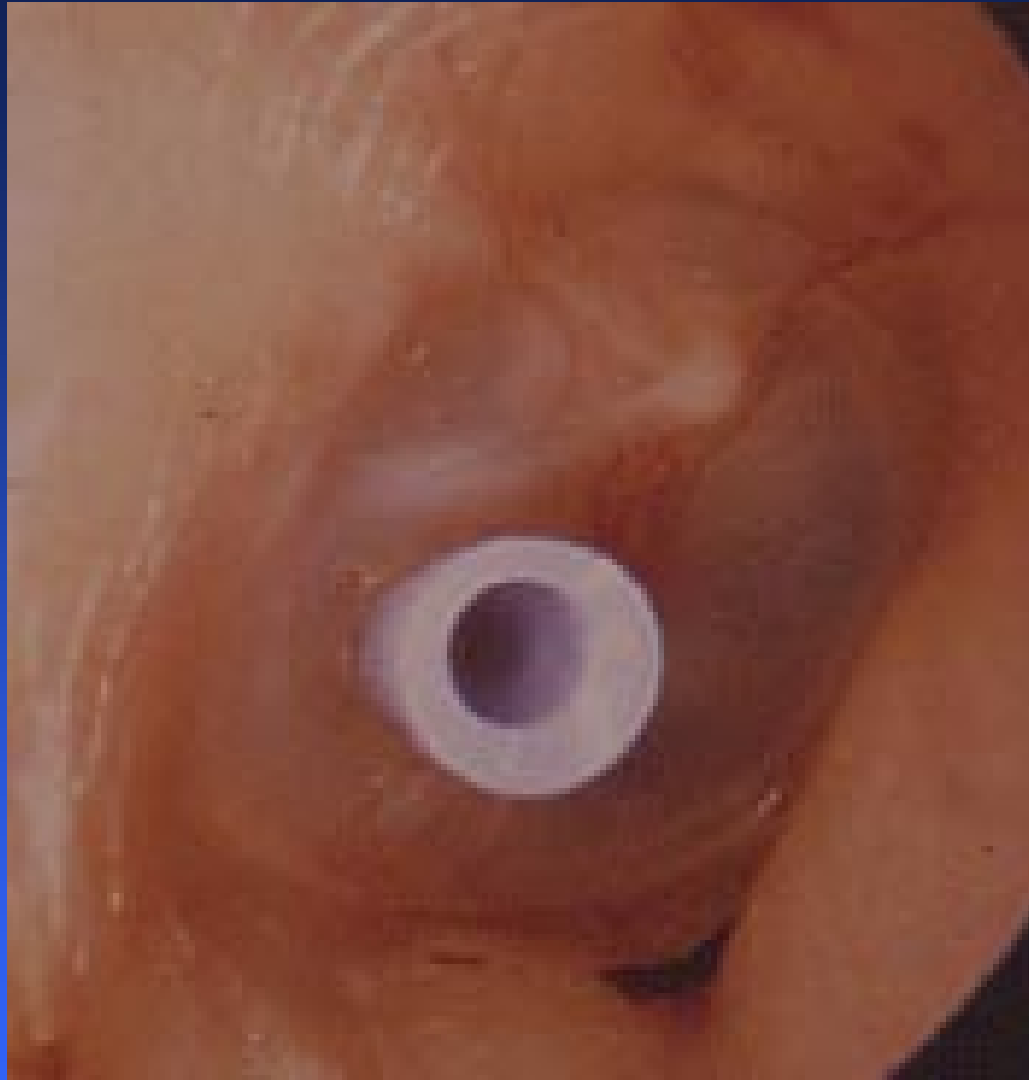

TARGET STUDY

- MRC funded randomised controlled trial
- Surgery v non-surgery



OME leading to 20 dB + loss > 12 weeks



? Watch - ? Grommets

TARGET STUDY

- Benefit in surgery group ...
 - hearing disability improved
 - Q of L scores
 - non-aggressive behaviour problems
 - (NOT Aggressive behaviour problems)

Basic Point

- A child that 'cant hear' cant hear till proved otherwise
- Hearing loss is underestimated

TOPICS

- TAKING A HISTORY
- (EXAMINATION)
- AUDIOGRAMS & HEARING LOSS
- CHRONIC EAR DISEASE
- VERTIGO
- TINNITUS
- GLUE EAR (TARGET STUDY)
- RHINITIS / SINUSITIS
- NECK & THROAT SYMPTOMS
 - HOARSE VOICE
 - DYSPHAGIA
 - THYROID / NECK LUMP
- ANYTHING ELSE

Back to basics



EXAMINATION - NOSE



EXAMINATION - NOSE



- External Inspection
- Airway
- Nasal Cavity
 - Auriscope
 - (Thudicums/ Head light)



EXAMINATION - NOSE



External Inspection



EXAMINATION - NOSE



The Airway

EXAMINATION OF NASAL CAVITY

Look for ...

Septum

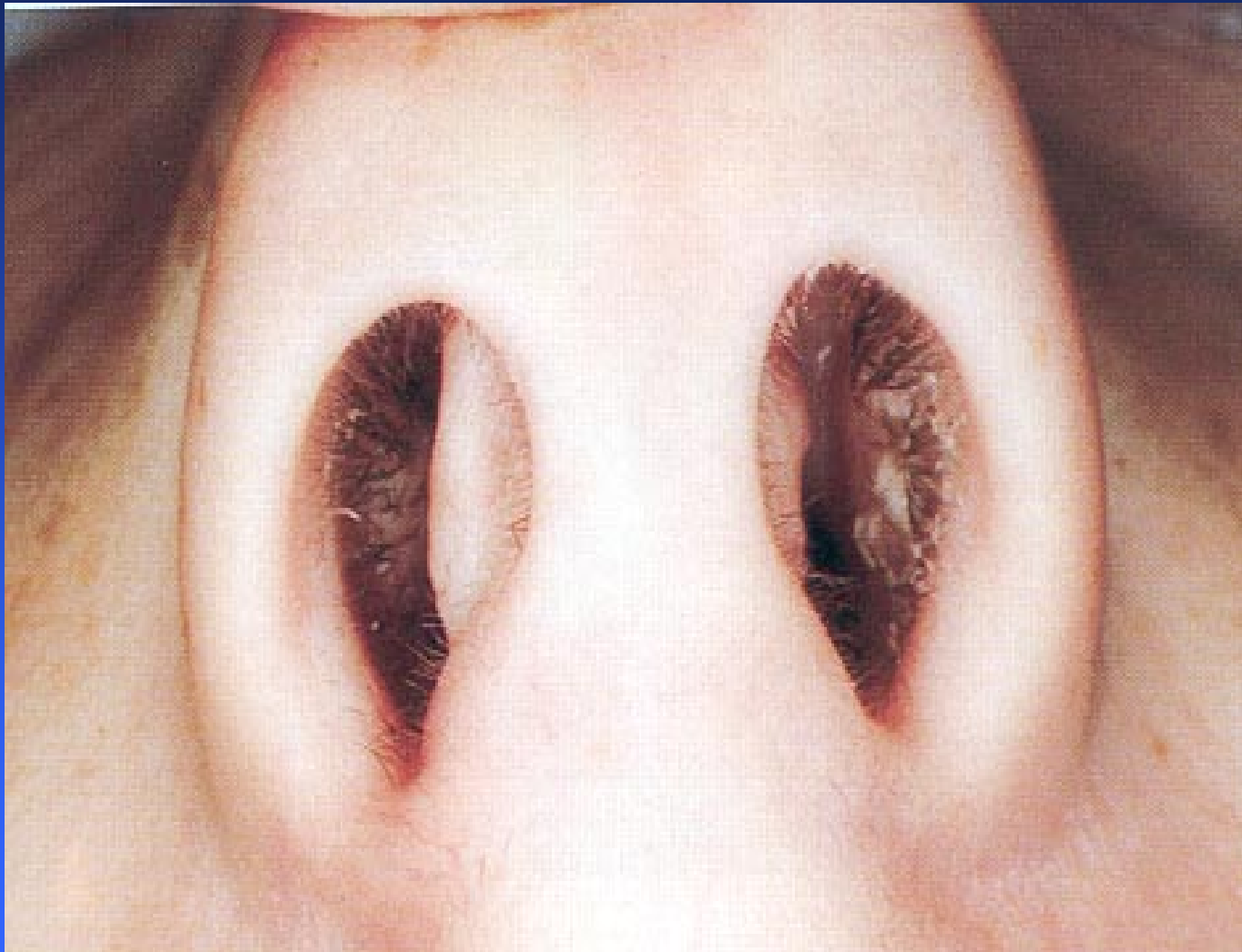
position

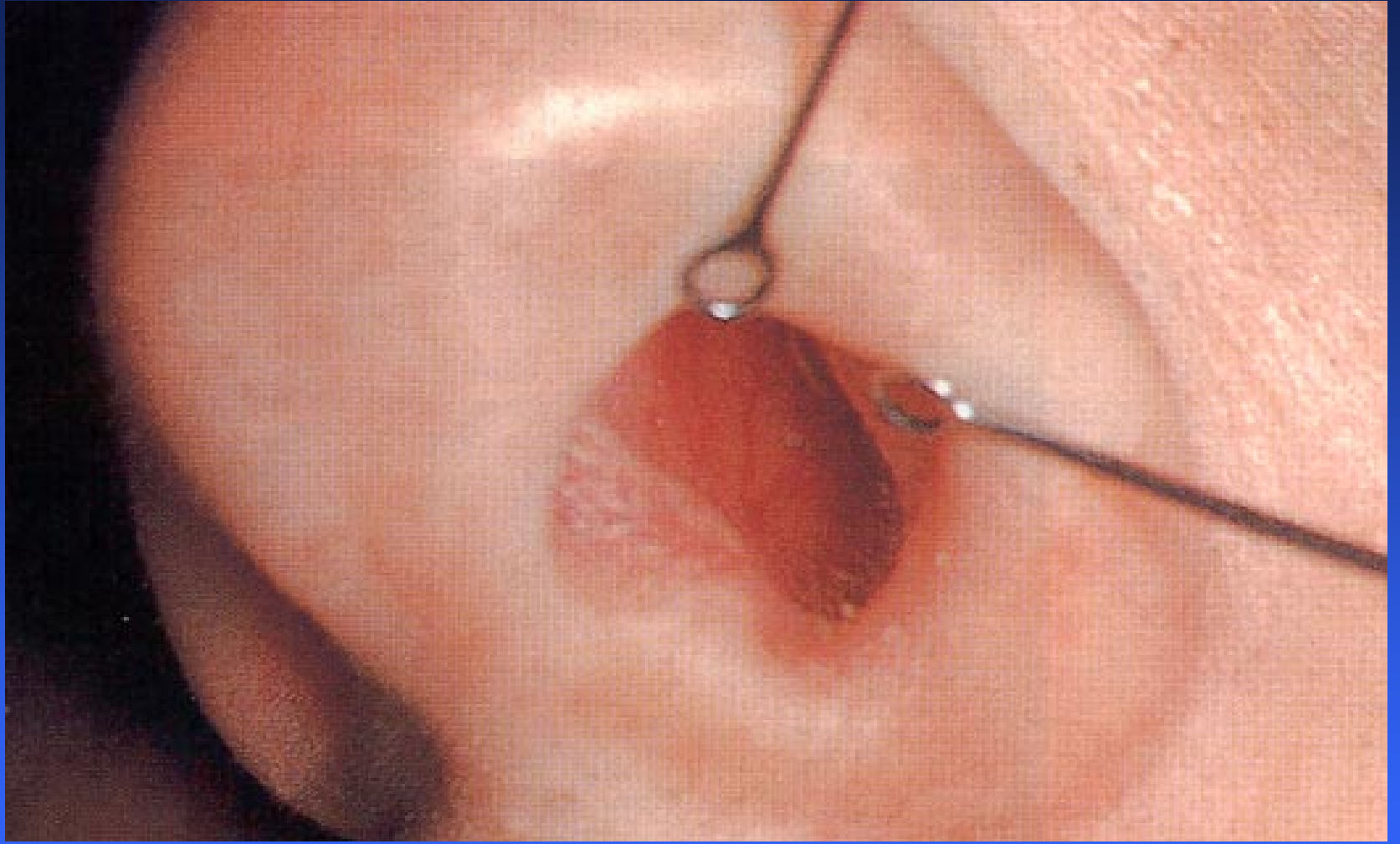
Little's area

Inferior

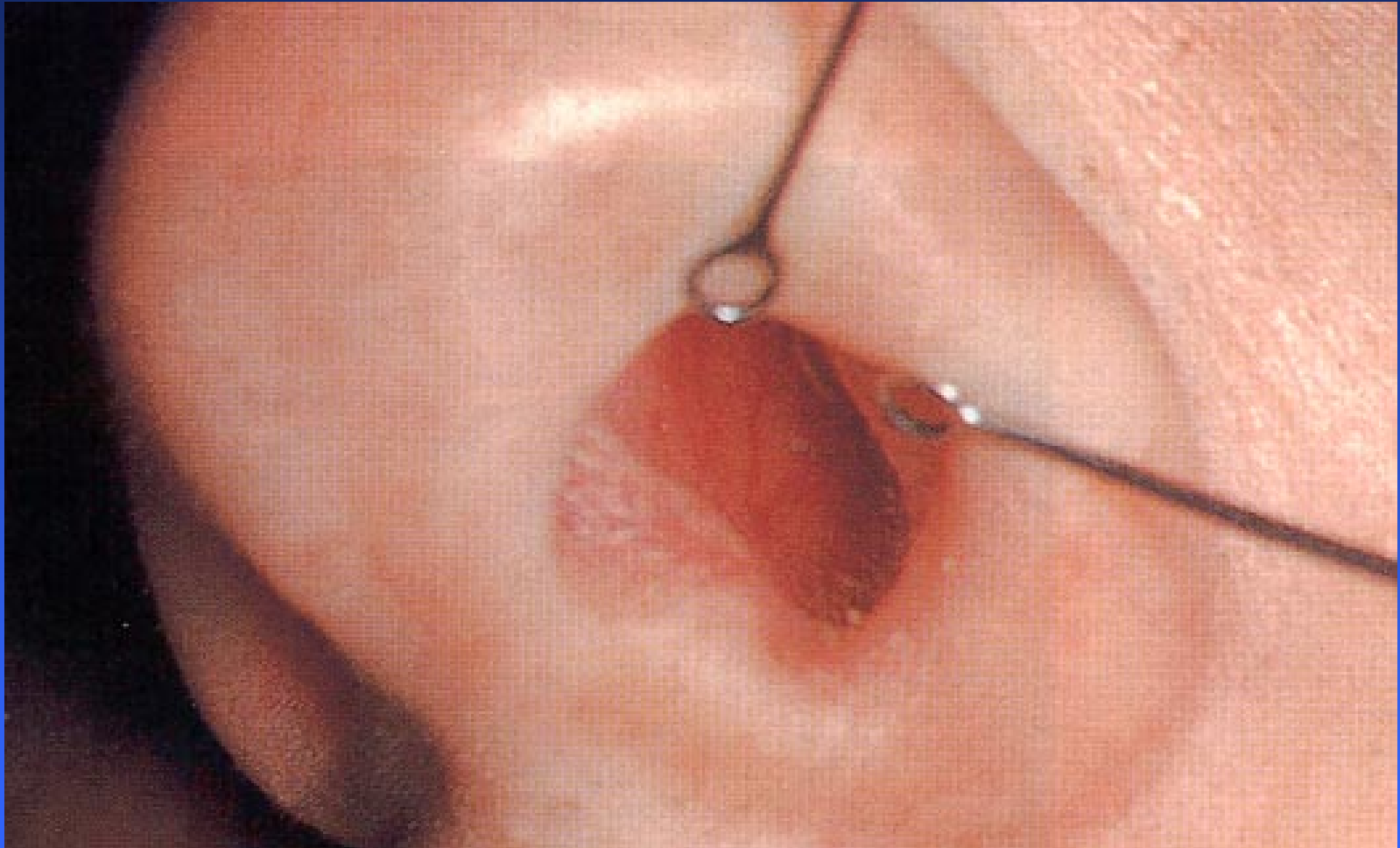
Turbinate

Septum - position

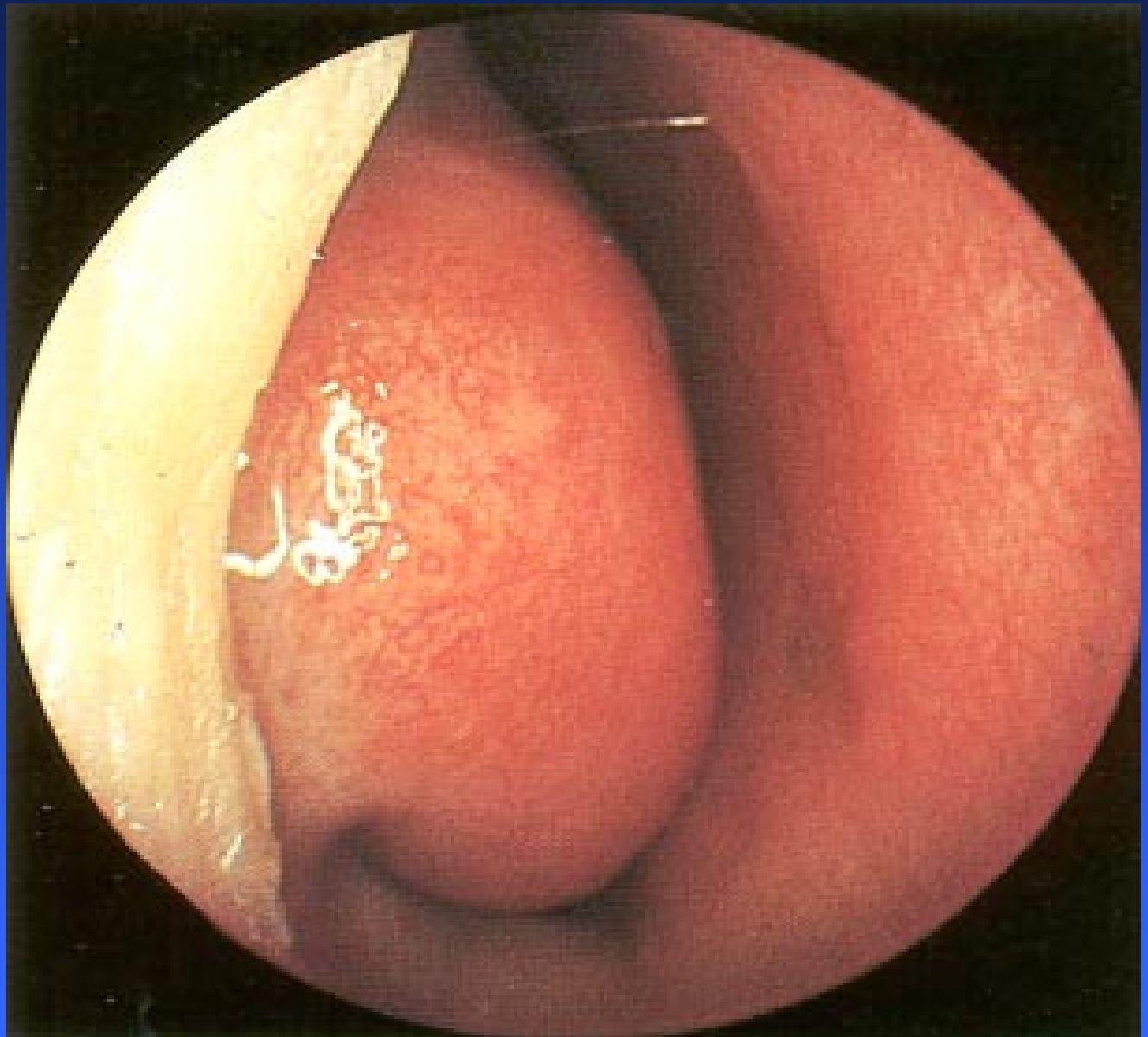




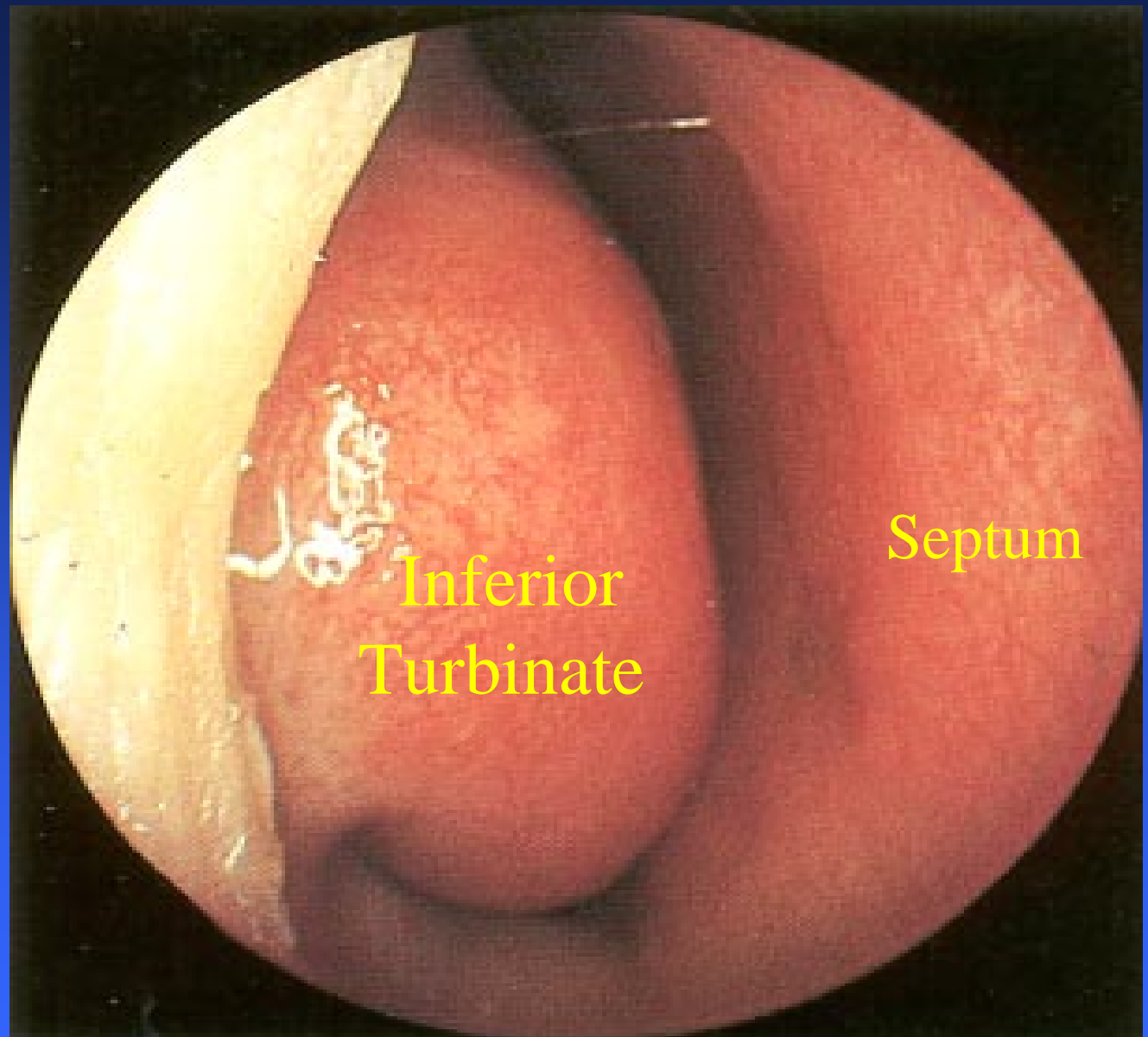
Septum - Little's area



EXAMN
OF
NASAL
CAVITY



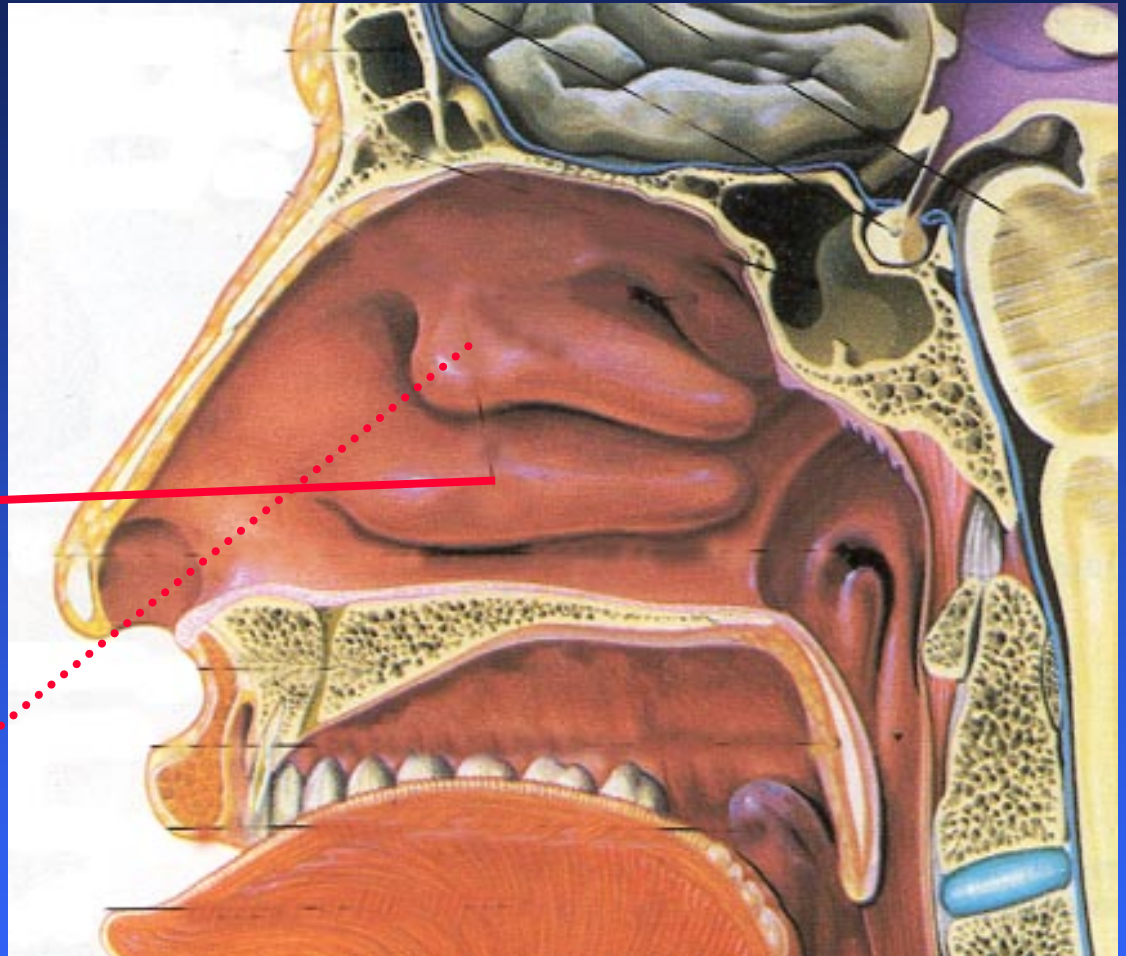
EXAMN
OF
NASAL
CAVITY



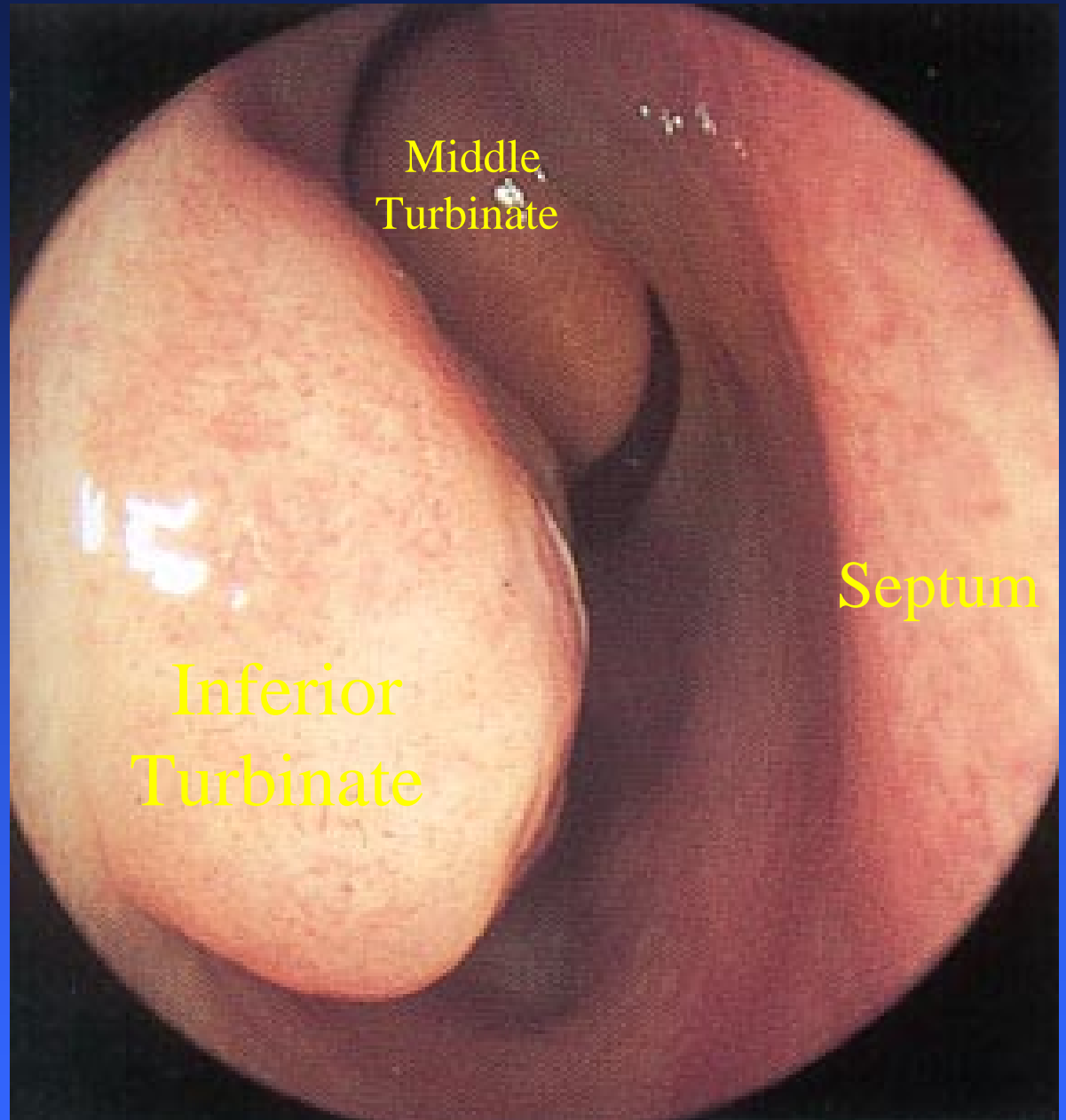
EXAMINATION OF NASAL CAVITY

Look for ...

- Inferior Turbinate
- ? ? Middle Turbinate



EXAMN
OF
NASAL
CAVITY



**RHINITIS (Rhinosinusitis) –
SYMPTOMS & TREATMENTS
IN PRIMARY CARE**



RHINITIS (Rhinosinusitis) – SYMPTOMS

- Nasal blockage
- Rhinorrhoea
- Post nasal discharge
- Facial pain / headache – not always sinuses
- Facial pressure
- Snoring / Cheek swelling / etc

Rhinosinusitis – investigations in primary care

- Allergy testing



- Sinus Xray

No use

RHINITIS (Rhinosinusitis) – Possible Treatments

- Antihistamines – oral
- Steroid sprays (drops)
- Antihistamine spray
- Antibiotics
- Ipratropium bromide spray
- Sodium cromoglycate spray
 - ? decongestants

PERENNIAL RHINITIS SINUSITIS

Summary

- ? Triggers / allergy
- Facial pain – not always sinuses
- Try antihistamines
- Try steroid nasal spray (4 weeks minimum)
- Refer in cases not responding to medical therapy
- Endoscopic sinus surgery possible

TOPICS

- TAKING A HISTORY
- (EXAMINATION)
- AUDIOGRAMS & HEARING LOSS
- CHRONIC EAR DISEASE
- VERTIGO
- TINNITUS
- GLUE EAR (TARGET STUDY)
- RHINITIS / SINUSITIS
- NECK & THROAT SYMPTOMS
 - HOARSE VOICE
 - DYSPHAGIA
 - THYROID / NECK LUMP
- ANYTHING ELSE

- HOARSE VOICE

- DYSPHAGIA


- THYROID / NECK
LUMPS




? Cancer !!!!!!!

Ear Nose & Throat problems - common in Primary Care

10-20% of all Consultations in GP



12 patients / week on average
(excluding URTI)



“ all patients with possible cancer will be seen in 2 weeks”



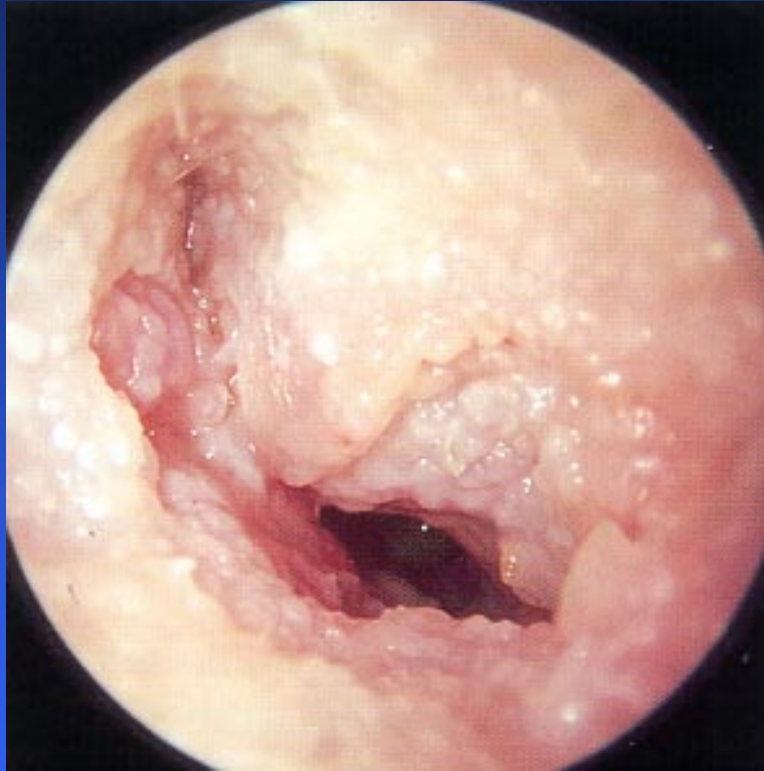What can be a sign of
'CANCER'



OTALGIA



OTORRHOEA



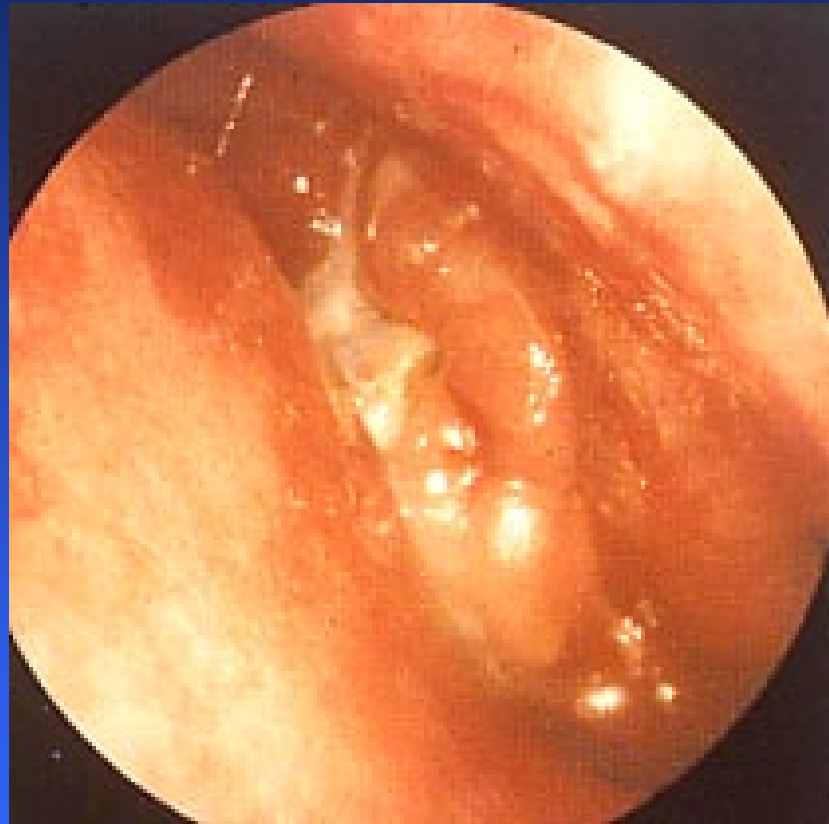BLEEDING



HEARING LOSS

NASAL OBSTRUCTION

EPISTAXIS

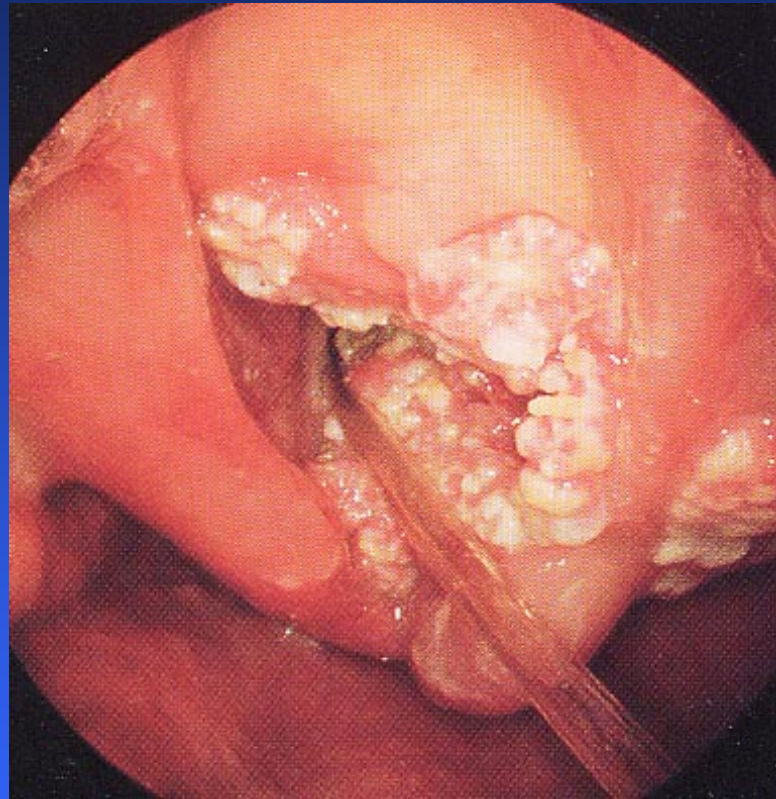


FACIAL PAIN

RHINORRHOEA

HOARSENESS

SENSATION IN THROAT



NECK LUMP

DYSPHAGIA

HOARSENESS

SENSATION IN THROAT

NASAL OBSTRUCTION

EPISTAXIS

OTALGIA

C

OTORRHOEA

FACIAL PAIN

RHINORRHOEA

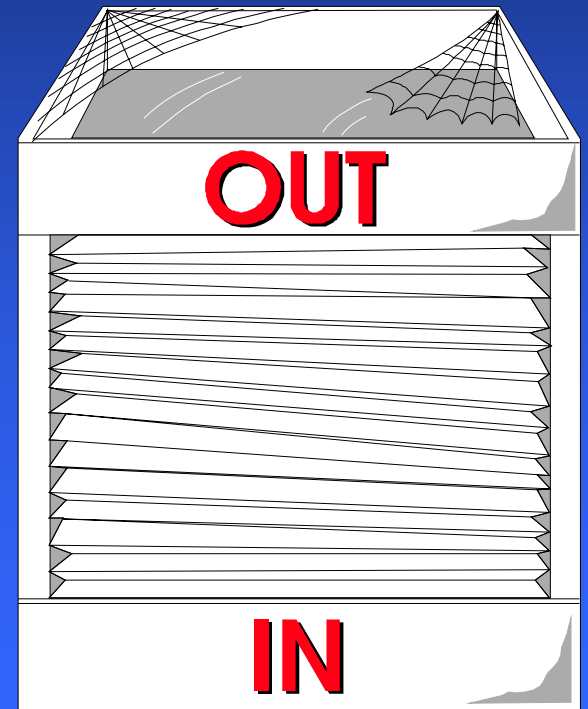
BLEEDING

HEARING LOSS

NECK LUMP

DYSPHAGIA

Referrals



HOARSENESS

SENSATION IN THROAT

NASAL OBSTRUCTION

EPISTAXIS

OTALGIA

C

OTORRHOEA

FACIAL PAIN

RHINORRHOEA


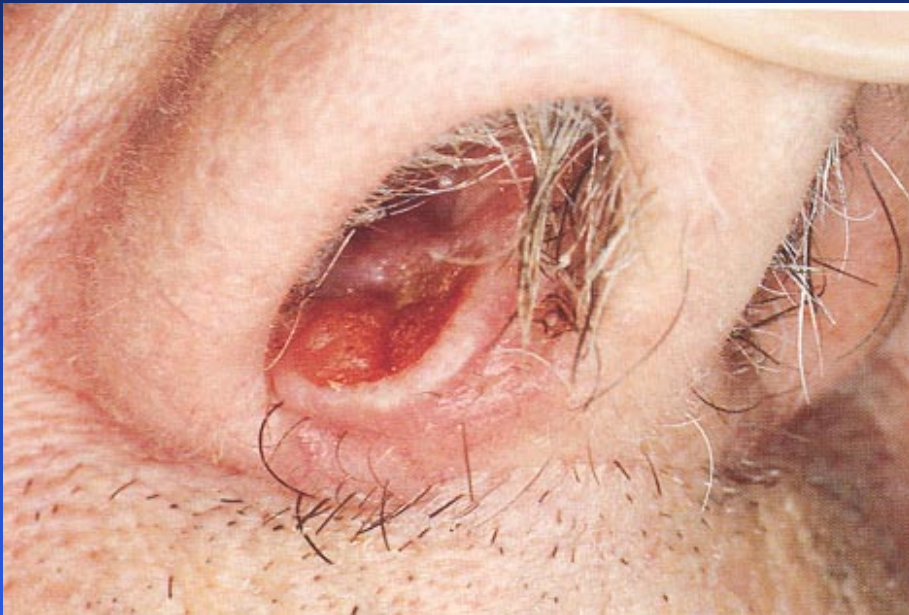
BLEEDING

HEARING LOSS

NECK LUMP

DYSPHAGIA

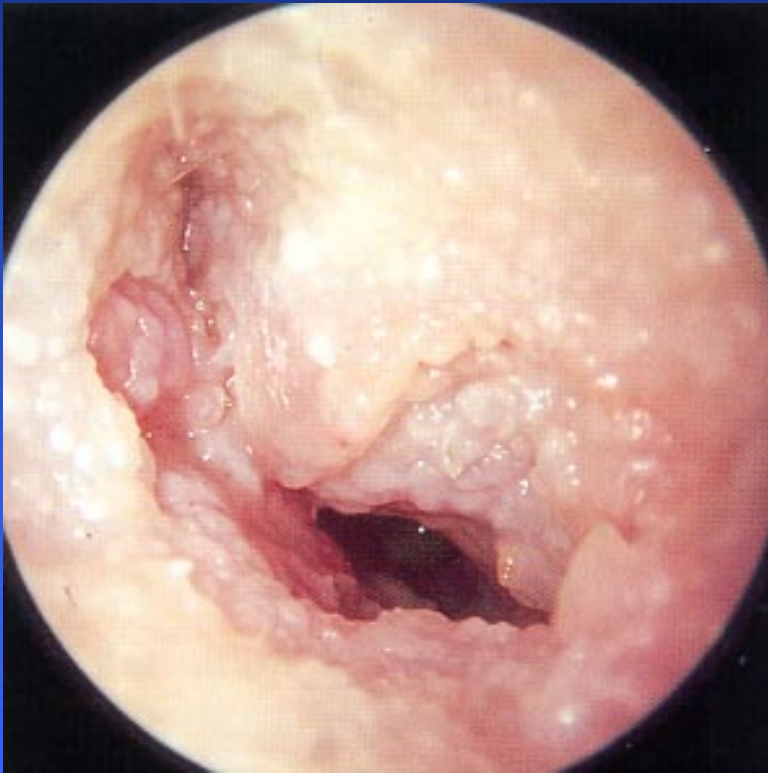Telling the difference



MR. D. R. STRACHAN	
URGENT	
SOON	
ROUTINE	
? TO SEE	



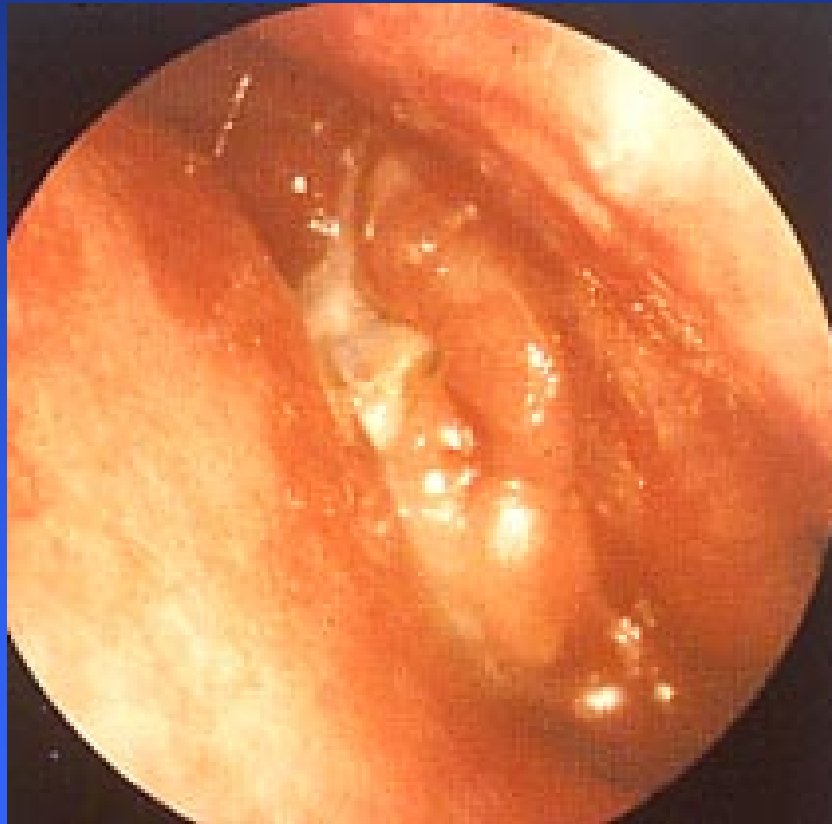OTALGIA
- Intractable
& Progressive



BLOOD
STAINED
OTORRHOEA



UNILATERAL SYMPTOMS



BLOOD
STAINED
RHINORRHOEA

FACIAL
SWELLING

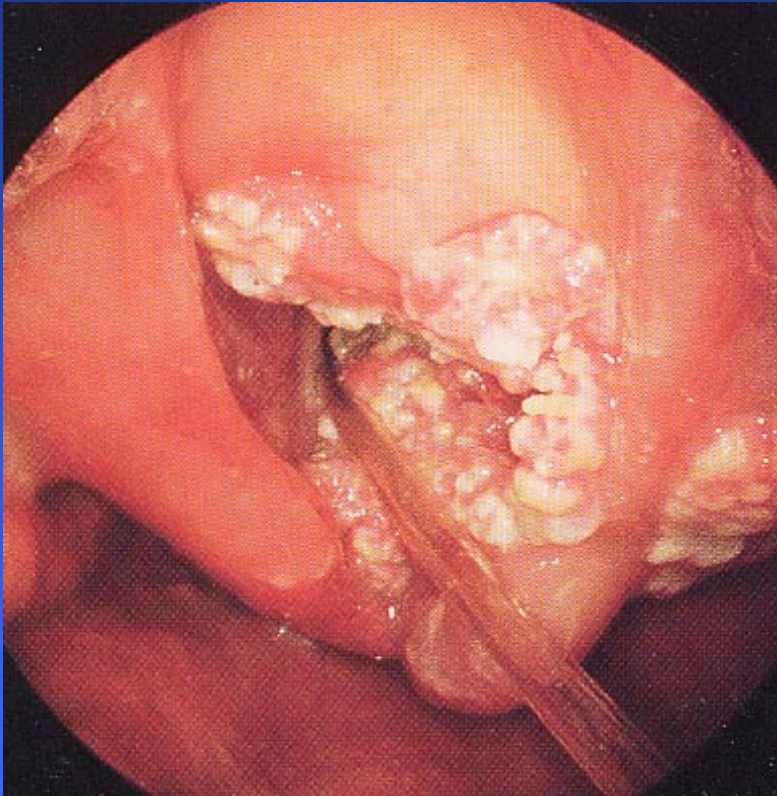


PERSISTENT HOARSENESS

PROGRESSIVE
DYSPHAGIA

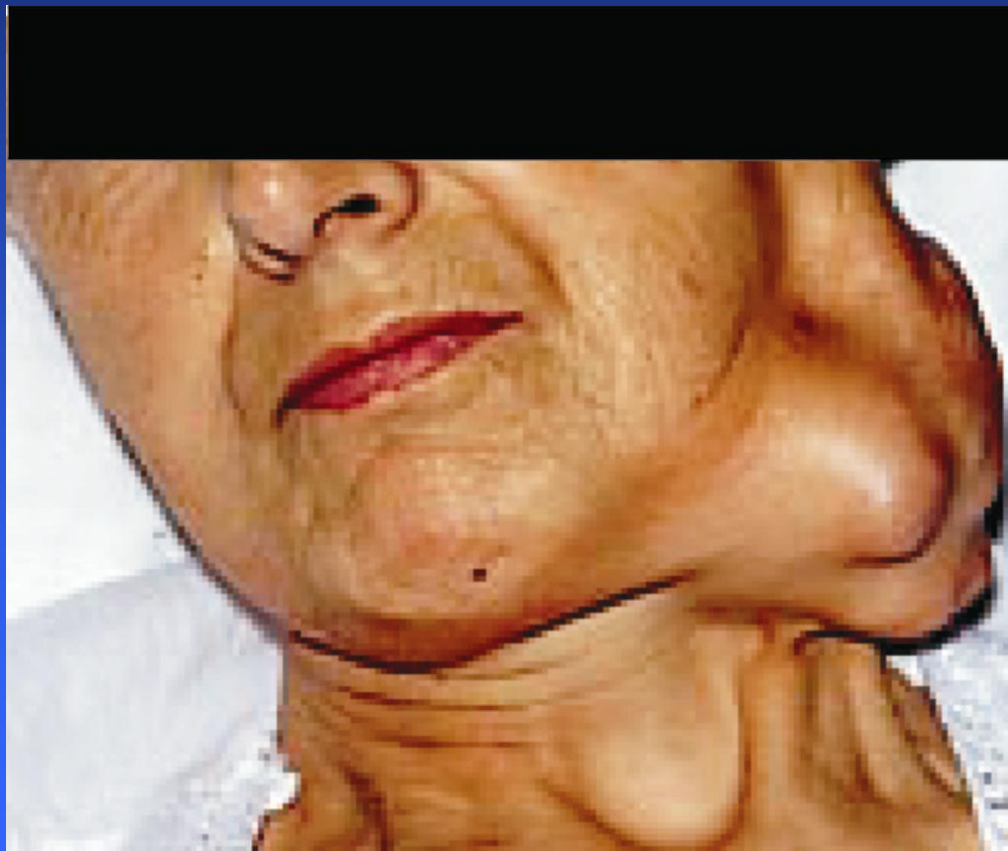THROAT
PAIN WITH
OTALGIA

ASSOCIATED
NECK LUMP

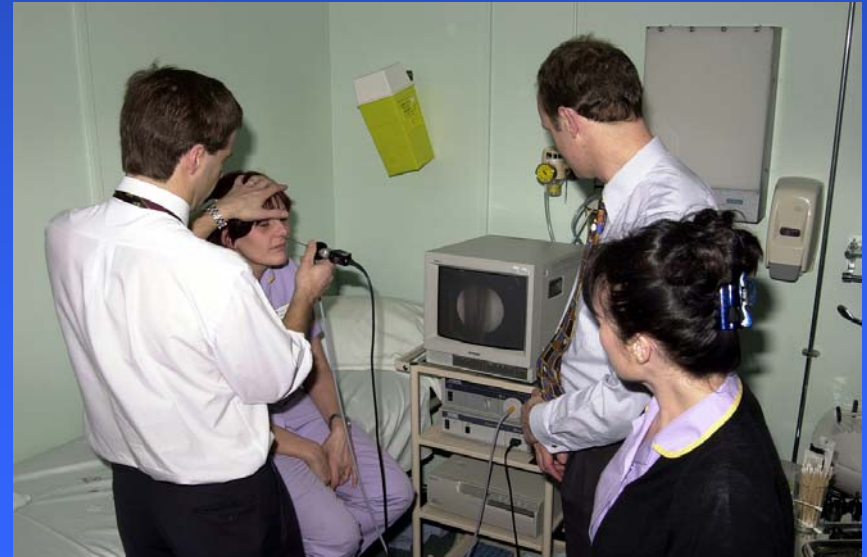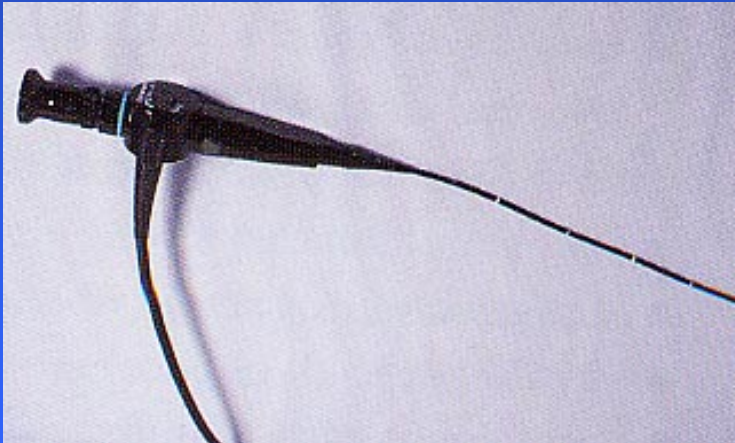

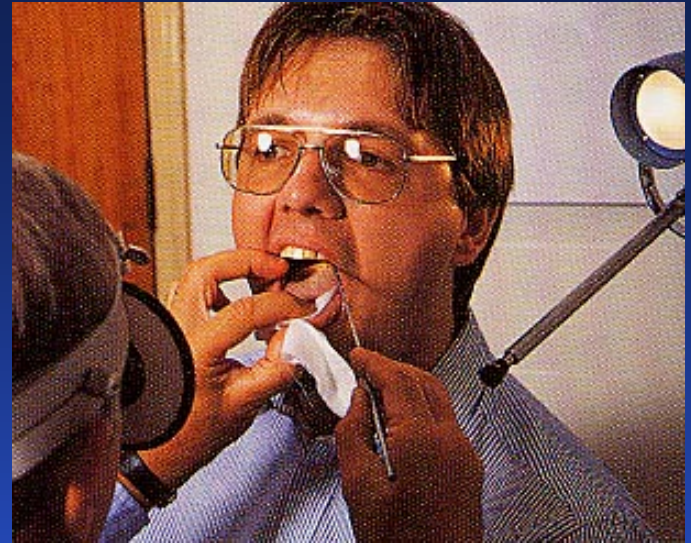
Neck Lumps

Think ENT



Neck Lumps
Need upper airway
i.e. ENT assessment

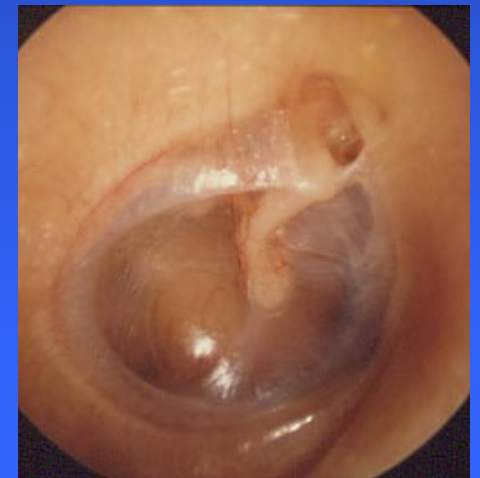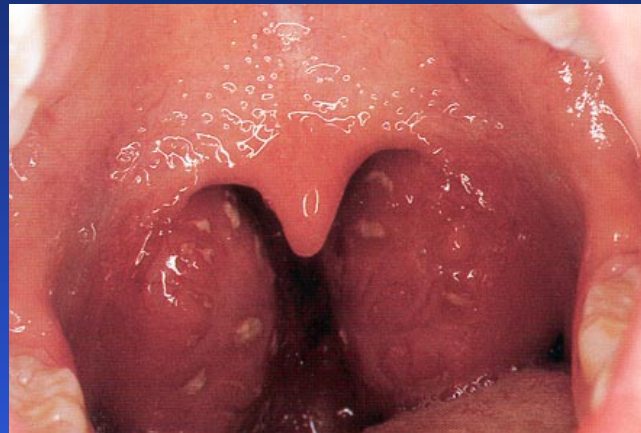
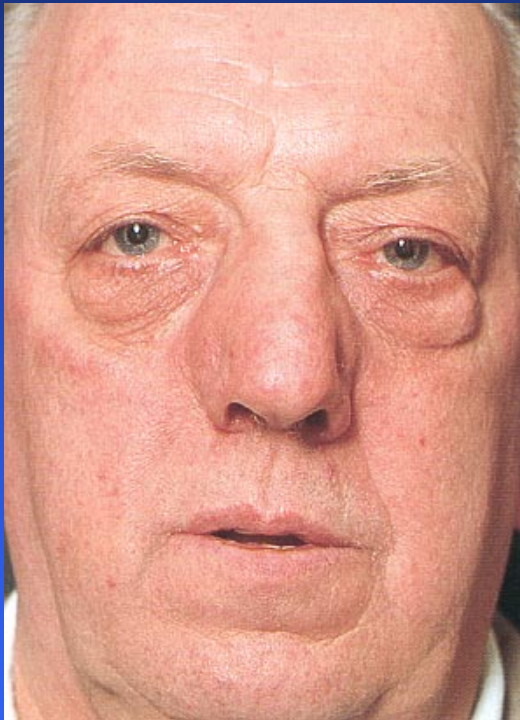


HOARSE VOICE DYSPHAGIA

- Progressive
- Never normal
- High risk patient
- Associated pain / otalgia

- Consider fast-track

Common things are common



Communication

The End

Discussion

Not quite

Basic Questions

1. Draw a normal eardrum
2. What normal structures can you see up a nose
3. What is a cholesteatoma
4. What is the commonest way for an acoustic neuroma to present
5. What may cause a facial palsy

Any questions



We're all ears!