

FIGURE 3. VOLUME-TIME CURVES (before and after bronchodilator)

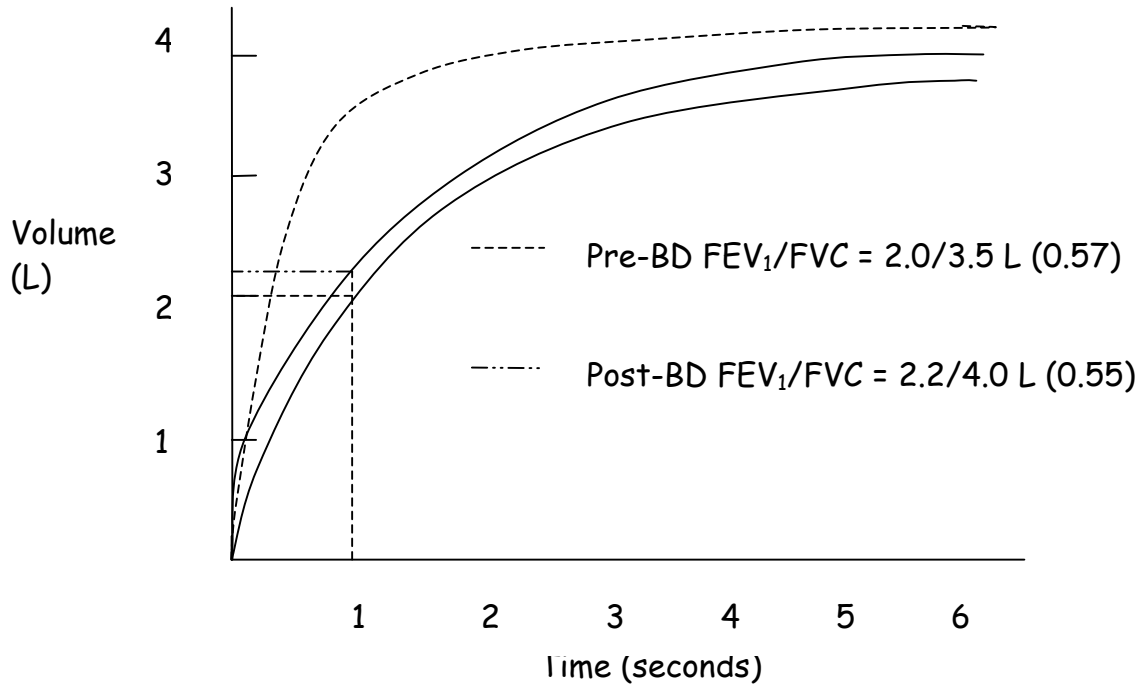


FIGURE 4. FEATURES OF VENTILATORY ABNORMALITY IN SPIROMETRY

	OBSTRUCTIVE	RESTRICTIVE	MIXED
FEV₁	REDUCED	REDUCED OR NORMAL	REDUCED
FVC	REDUCED OR NORMAL	REDUCED	REDUCED
FEV₁/FVC	REDUCED	NORMAL OR INCREASED	REDUCED

FIGURE 5. PATTERNS OF VENTILATORY ABNORMALITIES

(----- normal pattern; _____ abnormal pattern)

